

Role Of Balloon Bronchoplasty In A Fibrostenotic Type Of Endobronchial Tuberculosis

Rajamani Kasi, Gangadharan Vadivelu¹, Prasanth Gururaj^{*2}

¹MD Respiratory Medicine Department of Respiratory Medicine, Saveetha Medical college and Hospital, ²Saveetha Institution of Medical and Technical Science (SIMATS) Chennai, Tamil Nadu

Cite this paper as: Rajamani Kasi, Gangadharan Vadivelu, Prasanth Gururaj(2024). Role Of Balloon Bronchoplasty In A Fibrostenotic Type Of Endobronchial Tuberculosis. *Frontiers in Health Informatics*, 13 (8) 940-946

Abstract

A major challenge in the treatment of tuberculosis that affects the tracheobronchial tree, often leading to significant morbidity due to its complex presentation and diagnostic difficulties is presented by Endobronchial tuberculosis (EBTB). This case report details the management of a 19-year-old female diagnosed with fibrostenotic EBTB. Despite initial anti-tubercular therapy, persistent symptoms and significant bronchial narrowing necessitated intervention. The patient underwent serial flexible bronchoscope-guided balloon bronchoplasty, resulting in marked clinical improvement. Pulmonary function tests showed a notable increase in FEV1 from 48% to 59%. This report underscores the efficacy of balloon bronchoplasty in restoring airway patency and improving lung function in fibrostenotic EBTB, highlighting its potential as a standard therapeutic option. Early diagnosis and timely intervention are critical for managing this condition effectively, enhancing patient outcomes and quality of life.

Keywords: Endobronchial tuberculosis, Fibrostenotic EBTB, Balloon bronchoplasty, Airway patency, Pulmonary function improvement

Introduction:

A type of tuberculosis known as endobronchial tuberculosis (EBTB) targets the tracheobronchial tree (1) and diagnosing EBTB is very challenging because the clinical manifestations and radiological findings are non-specific and misleading (2). Despite being a significant cause of morbidity, EBTB remains difficult to identify with a chest X-ray (3). It occurs in approximately 10-40% of patients who have active tuberculosis, with the fibrostenotic type being particularly rare (4). Sputum culture continues to be the definitive diagnostic method, whereas Acid Fast Bacilli (AFB) microscopy, radiographic imaging, and the GeneXpert assay are commonly utilized diagnostic tools in countries such as Indonesia (2).

First reported in 1968, EBTB hinders complete recovery due to its complex nature (5). Bronchoscopic examinations may uncover hypertrophy with narrowing of the lumen, mucosal oedema, erosion, ulceration, cicatricial stenosis, or even complete stenosis (6). EBTB typically affects patients under 35 years old, presenting symptoms such as cough with expectoration, haemoptysis, breathlessness, and an irritable barking cough unresponsive to antitussive medication (7). Timely treatment and prevention of complications are crucial (8). However, early diagnosis is frequently hindered by the low positivity rate of acid-fast bacillus staining in sputum smears and the non-specific radiological and clinical presentations (9). Sputum examination is the initial step in diagnosing EBTB(4). When sputum results are negative or chest radiographs are inconclusive, computed tomography and bronchoscopy become essential tools of investigation (6). Advancements in interventional bronchoscopy have significantly improved the management of tracheobronchial stenosis (10). This case underscores the need to emphasize early and accurate diagnosis, timely intervention, and continuous advancements in interventional techniques to manage endobronchial tuberculosis effectively.

Case Presentation:

In this case report, a 19-year-old woman came to the clinic after experiencing a cough and noticeable weight loss for two months. Upon initial examination she was alert and had a normal respiratory rate of 20 breaths per minute, 72 beats per minute heart rate, and blood pressure reading of 110/70 mmHg. Her oxygen levels were at 97% while breathing normally. No abnormalities were observed in her routine blood tests. Her erythrocyte sedimentation rate (ESR) was higher, at 35 mm/hr. Despite a Mantoux test and inconclusive sputum analysis the chest X ray did not reveal any issues. (Figure: 1). Given the persistence of her symptoms and the inconclusive initial findings, a CT scan of the thorax was performed (Figure: 2). The scan demonstrated centrilobular nodules with a linear branching pattern in the right lower lobe, which raised the suspicion of tuberculosis. To further investigate, a flexible bronchoscopy was conducted. During the procedure, an intraluminal growth with caseous necrotic material was observed near the right 6th segment, which appeared significantly narrowed, barely allowing the passage of the bronchoscope (Figure: 3-5). A biopsy was taken from this region for further analysis.

Histopathological examination of the biopsy samples revealed features consistent with granulomatous inflammation. Additionally, *Mycobacterium tuberculosis* (MTB) was detected with bronchoalveolar lavage (BAL) testing using cartridge-based nucleic acid amplification test (CBNAAT), which was sensitive to Rifampicin. Based on these findings, the patient was diagnosed with tuberculosis and was subsequently started on a regimen of anti-tubercular therapy (ATT) that included Isoniazid (INH), Ethambutol (EMB), Pyrazinamide (PZA), and Rifampicin (RIF).

At the onset of treatment, the patient's pulmonary function test (PFT) indicated a reduced forced expiratory volume in one second (FEV1) of 48%. After two weeks of ATT, the patient was readmitted for further intervention due to persistent symptoms and significant bronchial narrowing. She underwent serial flexible bronchoscope-guided balloon bronchoplasty to address the stenosis in the right 6th segment. During the initial bronchoplasty sessions, small balloons and low pressure were employed. In subsequent sessions, the pressure and diameter of the balloons were progressively increased. The balloons were inflated to pressures ranging from 3 to 10 times atmospheric pressure for durations of 20 to 120 seconds. Each session involved 3 to 4 rounds of serial dilation, performed at intervals of 2 to 3 minutes.

Following the series of bronchoplasty procedures, the patient's condition showed marked improvement. A repeat pulmonary function test demonstrated an improvement in lung function, with an FEV1 of 59%. One month later, a follow-up bronchoscopy was performed to assess the status of the previously stenosed right 6th segment. The follow-up bronchoscopy revealed that the segment was now dilated and patent, with no signs of congestion or swelling, and the bronchoscope could pass through without any obstruction.

Discussion:

A notable complication of pulmonary tuberculosis (TB), occurring in approximately 5.8% of TB cases is the Endobronchial tuberculosis (EBTB)(8). This condition is more prevalent in females, likely due to their narrower bronchi, which makes them more susceptible to higher stenosis grades and multiple-level EBTB (11). The majority of EBTB cases are observed in the second and third decades of life, with a secondary peak in the elderly population (12). EBTB can affect any segment of the bronchial tree, most commonly targeting the primary bronchi, the right middle lobar bronchus, and the bilateral superior lobar bronchi (8). It involves various layers of the tracheobronchial wall, including the lamina muscularis and cartilage, leading to a highly variable clinical course influenced by the interaction between mycobacteria, host immunity, and anti-tuberculosis drugs (3).

Chung and colleagues classified EBTB into seven distinct subtypes based on bronchoscopy appearances: fibrostenotic, actively caseating, tumorous, granular, edematous-hyperemic, nonspecific bronchitis, and ulcerative (13). Each subtype presents distinct clinical manifestations, making EBTB challenging to diagnose due to its non-distinctive symptoms such as cough, haemoptysis, decreased appetite, general weakness, fever, dyspnoea, wheezing, and decreased breath sounds (8, 14). Diagnosis is often confirmed through bronchoscopy, which is the most valuable tool, supplemented by biopsy,

brushings, needle aspiration, and bronchoalveolar lavage, as chest X-rays and sputum smear tests for Acid-fast bacillus frequently yield inconclusive results (5, 8, 14).

In the presented case, a 19-year-old female with symptoms of cough with expectoration and significant weight loss over two months was evaluated. Initial examinations, including a chest X-ray, were inconclusive. However, a CT scan revealed centrilobular nodules in the right lower lobe, raising suspicion of TB. Bronchoscopy revealed an intraluminal growth with caseous necrotic material near the right 6th segment, leading to significant narrowing. Histopathological examination and CBNAAT testing confirmed the presence of *Mycobacterium tuberculosis*, sensitive to Rifampicin. The patient was diagnosed with TB and started on a regimen of anti-tubercular therapy. Despite initial treatment, persistent symptoms and significant bronchial narrowing necessitated further intervention with serial flexible bronchoscope-guided balloon bronchoplasty.

Balloon bronchoplasty has become a preferred minimally invasive procedure for treating fibrostenotic EBTB (4, 15). This technique involves the sequential inflation of balloons within the stenosed airway to dilate the bronchial lumen. In this case, the patient underwent several sessions of balloon bronchoplasty, starting with small balloons at low pressure, progressively increasing the diameter and pressure of the balloons in subsequent sessions. The procedure resulted in marked improvement in the patient's condition, with a significant increase in FEV1 from 48% to 59% after the interventions.

The significance of this case study lies in highlighting the efficacy of balloon bronchoplasty as a therapeutic option for fibrostenotic EBTB. This procedure not only provides immediate relief from bronchial obstruction but also contributes to the long-term management of the condition. Despite the initial success, long-term follow-up is essential to monitor and address potential complications such as pneumothorax, mediastinal emphysema, and tracheal and bronchial wall lacerations (7, 16). Other modalities, such as electrocautery and the application of Mitomycin C, may be considered to minimize these complications (17).

Balloon bronchoplasty stands out as a safe and effective intervention, restoring airway patency and improving lung function in patients with fibrostenotic EBTB. The case underscores the importance of early diagnosis and timely intervention in managing complex cases of EBTB, thereby enhancing patient outcomes and quality of life (8, 18). Continued research and clinical trials are necessary to further refine this technique and establish comprehensive treatment protocols for EBTB, ensuring optimal care for affected individuals (11, 19).

Conclusion

This case report highlights the effective role of balloon bronchoplasty in treating fibrostenotic endobronchial tuberculosis (EBTB). The significant improvement in lung function and airway patency in the 19-year-old patient demonstrates the efficacy of this minimally invasive intervention. For healthcare professionals, this case emphasizes and signifies the importance of early diagnosis coupled with timely intervention in managing complex EBTB cases. Balloon bronchoplasty's ability to restore airway patency and enhance lung function makes it a valuable therapeutic option. The step-by-step account of the procedure provides practical insights for clinicians.

This report adds to the evidence supporting balloon bronchoplasty for fibrostenotic EBTB, advocating its consideration as a standard treatment. Further research and clinical trials are necessary to refine this technique and establish comprehensive treatment protocols, ultimately enhancing patient outcomes and quality of life. The insights from this case can guide future clinical practice, ensuring better care for those affected by this challenging form of tuberculosis.

Authors contribution:

Rajamani Kasi collected and interpreted the data. Rajamani Kasi and Gangadharan Vadivelu drafted the manuscript. Prasanth Gururaj critically reviewed and revised the manuscript. All authors contributed equally and agreed to be accountable for all aspects of the work.

Acknowledgement:

The authors sincerely thank Dr. Kevin Kumar Vijayakumar, M. Tech., Ph.D., from GRACE POLYCLINIC, Madurai, for his invaluable guidance and support during the preparation of this manuscript.

Conflict of Interest:

The authors report no conflicts of interest.

Funding:

The authors confirm that no external financial support was received for this study.

Declaration:

Ethical Approval:

This study received approval from the Institutional Ethics Committee at Saveetha Medical College. Written informed consent was obtained from the patient, a 19-year-old woman, who was fully informed about the study procedures before participation.

Use of AI and AI-Assisted Technologies:

Generative AI and AI-assisted tools were utilized in preparing this manuscript. ChatGPT 4.0 was used for structuring, Grammarly for grammar and spelling checks, and QuillBot for paraphrasing and proofreading. The authors take full responsibility for the final content.

Reference:

1. Lewinsohn DM, Leonard MK, LoBue PA, Cohn DL, Daley CL, Desmond E, et al. Official American Thoracic Society/Infectious Diseases Society of America/Centers for Disease Control and Prevention clinical practice guidelines: diagnosis of tuberculosis in adults and children. *Clinical Infectious Diseases*. 2017;64(2):e1-e33.
2. Susilawati TN, Larasati R. A recent update of the diagnostic methods for tuberculosis and their applicability in Indonesia: a narrative review. *Medical Journal of Indonesia*. 2019;28(3):284-91.
3. Ahmadi Hoseini SH, Ghalehnavi E, Amini M. Clinical and para-clinical presentations of endobronchial tuberculosis. *Journal of Cardio-Thoracic Medicine*. 2015;3(4):371-4.
4. Aneja A, Krishnaswamy UM, Thyagaraj V, Moideen RP, Satya Padmaja M. Endobronchial tuberculosis: two case reports and review of the literature. *Case reports in pulmonology*. 2014;2014(1):283972.
5. Hoheisel G, Chan B, Chan C, Chan K, Teschler H, Costabel U. Endobronchial tuberculosis: diagnostic features and therapeutic outcome. *Respiratory Medicine*. 1994;88(8):593-7.
6. Prasad R, Singh A. Role of bronchoscopy in diagnosis of smear-negative pulmonary tuberculosis. *Egyptian Journal of Bronchology*. 2019;13:1-5.
7. Putra MA, Billy M, Ardaya R, Ekasiwi RH, Rahmawati S, Sumarsudi KH. Surgical Intervention for Endobronchial Tuberculosis with Total Bronchial Occlusion: A Case Report. *The New Ropanasuri Journal of Surgery*. 2022;7(2):9.
8. Xue Q, Wang N, Xue X, Wang J. Endobronchial tuberculosis: an overview. *European journal of clinical microbiology & infectious diseases*. 2011;30:1039-44.
9. Arliny Y, Mursalin DS. Endobronchial Tuberculosis: Diagnosis and Treatment Approach. *Respiratory Science*. 2021;2(1):45-54.
10. Seo W, Kim HW, Kim JS, Min J. Long term management of people with post-tuberculosis lung disease. *The Korean Journal of Internal Medicine*. 2024;39(1):7.
11. Shahzad T, Irfan M. Endobronchial tuberculosis—a review. *Journal of thoracic disease*. 2016;8(12):3797.
12. Jung SS, Park HS, Kim JO, Kim SY. Incidence and clinical predictors of endobronchial tuberculosis in patients with pulmonary tuberculosis. *Respirology*. 2015;20(3):488-95.
13. Chung HS, Lee JH. Bronchoscopic assessment of the evolution of endobronchial tuberculosis. *Chest*. 2000;117(2):385-92.

14. Lee JH, Turk SS, Lee DH, Shin DH, Yang SC, Yoo BM. Endobronchial tuberculosis: clinical and bronchoscopic features in 121 cases. *Chest*. 1992;102(4):990-4.
15. Hautmann H, Gamarra F, Pfeifer KJ, Huber RM. Fiberoptic bronchoscopic balloon dilatation in malignant tracheobronchial disease: indications and results. *Chest*. 2001;120(1):43-9.
16. Wong JS, Ng CS, Lee TW, Yim AP. Bronchoscopic management of airway obstruction in pediatric endobronchial tuberculosis. *Canadian respiratory journal*. 2006;13(4):219-21.
17. Pulle MV, Asaf BB, Puri HV, Bishnoi S, Kumar A. Surgical intervention is safe, feasible, and effective in tubercular tracheobronchial stenosis. *Lung India*. 2021;38(3):245-51.
18. Kashyap S, Mohapatra PR, Saini V. Endobronchial tuberculosis. *Indian Journal of Chest Diseases and Allied Sciences*. 2003;45(4):247-56.
19. Casali L, Crapa ME. Endobronchial Tuberculosis: a peculiar feature of TB often underdiagnosed. Springer; 2012. p. 1-3.

Figure-1: Chest X-ray revealing lungs with no abnormalities.

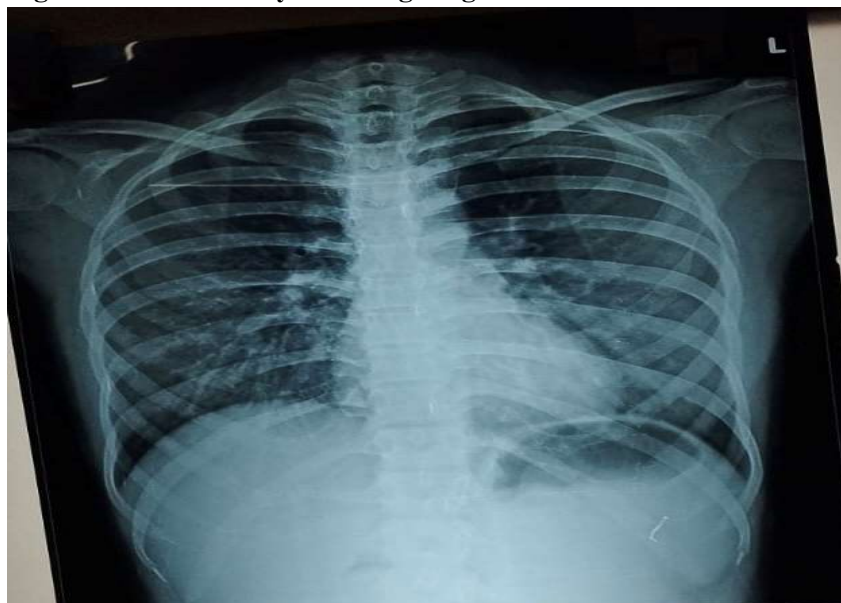


Figure-2: CT scan of the thorax revealing centrilobular nodules with a linear branching pattern in the right lower lobe.

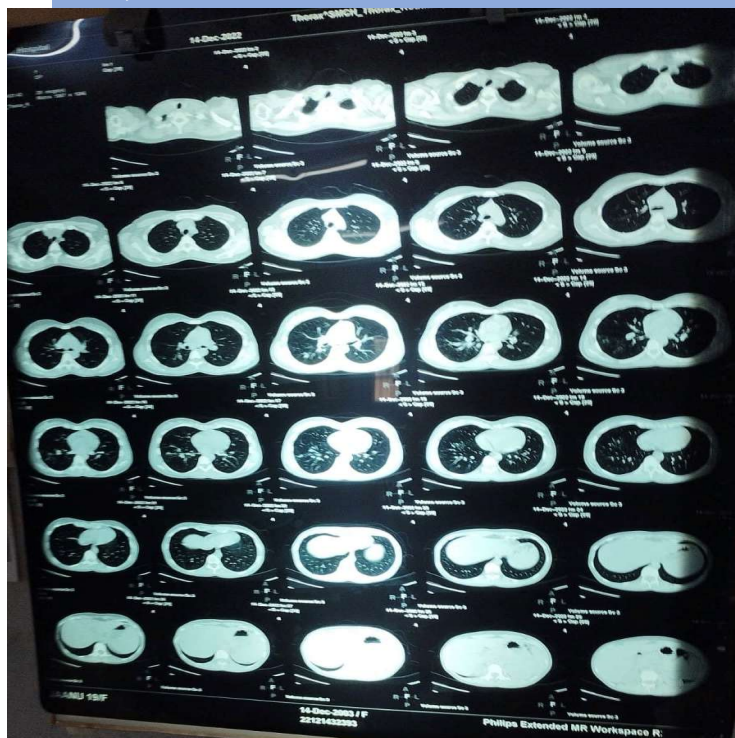


Figure-3: Flexible bronchoscopy examination of Right 6th Segment Narrowed.

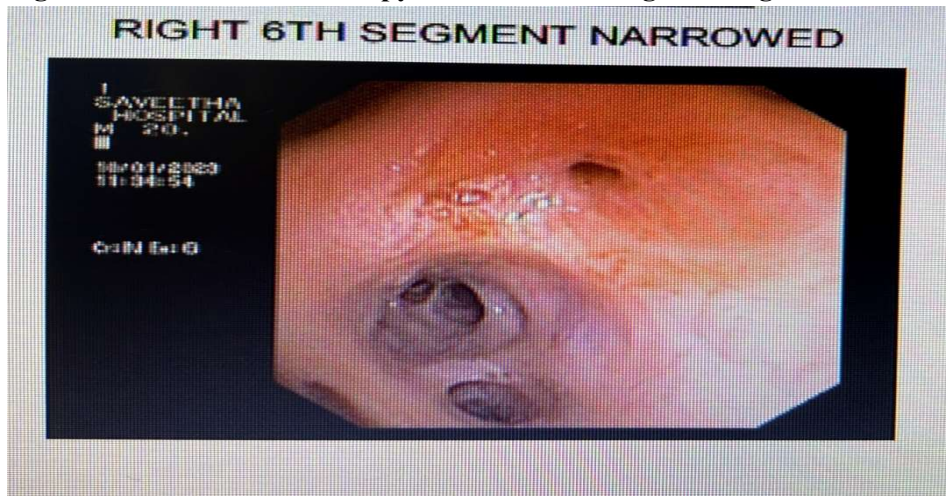

Figure-4: Flexible bronchoscopy examination of Narrow right lower lobe.

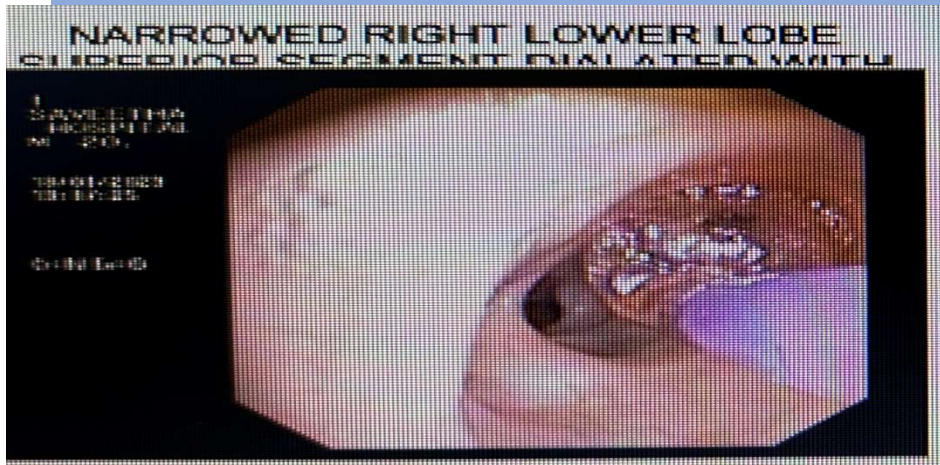

Figure-5: Flexible bronchoscopy examination of Dilated right lower lobe.

