

Advantages and Disadvantages of Using an Infrared Imaging System for Breast Cancer Detection

Mohammed Hassoon Alwan¹ Auns Qusai Al-Neami¹,
Haydar Hamza Alabedi²,

¹Biomedical Engineering Department, College of Engineering-Al-Nahrain University, Baghdad-Iraq
bmemhammed19801983@gmail.com

¹Biomedical Engineering Department, College of Engineering-Al-Nahrain University, Baghdad-Iraq
auns.q.hashim@nahrainuniv.edu.iq

²College of medicine, Baghdad University, Baghdad-Iraq.
haydar.h@comed.uobaghdad.edu.iq

Cite this paper as: Mohammed Hassoon Alwan, Auns Qusai Al-Neami, Haydar Hamza Alabedi (2024) Advantages and Disadvantages of Using an Infrared Imaging System for Breast Cancer Detection. *Frontiers in Health Informatics*, 13 (3), 3187-3195

Abstract:

The breast is an important part of the human body because this organ represents the Femininity sign for females in general and the milk production system for neonatal nutrition in especial. The breast cancer represents about 11.6% of newly recorded cases [1] where the newly recorded cases reached (2,500,000) cases globally in 2022(i.e. 290,000 new cases of breast cancer were recorded in 2022).

The breast cancer in its late stages is a dangerous disease that may lead to mastectomy (total or partial) or death while the early diagnosis can be cured easily and faster than a late-stage diagnosis. Infrared Imaging systems provide a non-invasive, safe, accepted cost, and no radiation procedure [2] for the early diagnosis purpose as well as it reliable complementary diagnostic tool.

Each living organism has a temperature higher than absolute zero (23 C°) [3] and emits particular infrared radiation associated with its overall metabolic activity. The temperature pattern of a normal and healthy human body is bilaterally symmetrical along the sagittal axis [4]. Malignant proliferation within the human body can disrupt its regular functioning due to its aberrant development without regulation of the DNA, resulting in alterations in its thermal pattern. In addition to its advantages as a non-radiation, no-touch, non-invasive, and recognized cost diagnostic technique, thermal imaging [5] [6] (i.e. functional imaging) can help diagnose cancer at the precancerous or early stage. Also, thermography has advantages and disadvantages that will be discussed briefly in the discussion and conclusion.

Keywords: *medical diagnosis, breast cancer, infrared imaging, infrared radiation.*

Introduction:

The battle against cancer began around a century ago and relies on two technical tools: treatment, which falls under the responsibility of medical schools, and diagnosis, which falls under the responsibility of engineering schools, particularly the Biomedical Engineering department. The outcomes of this battle include the development of X-rays, Computed Tomography (CT Scan), positron emission tomography (PET Scan), Magnetic Resonance Imaging (MRI), Ultrasound Imaging, and Single positron emission tomography (SPECT Scan) modalities. Where X-ray, CT, and MRI provide anatomical information [7] about the target organ while PET CT and SPECT CT provide functional information about the target organ, finally Infrared Imaging Systems [8] provide functional information about the target too. Yet, another modality that has emerged as a viable supplementary diagnostic tool is the Infrared Imaging system [9].

Cancer:

Malignant neoplasms are characterized by uncontrolled proliferation of abnormal cells that might potentially invade adjacent healthy organs. Prior to exploring the elucidation of the imaging process, it is important to establish clear definitions for certain terms [3]. Neoplasia refers to the process or mechanism by which a neoplasm, which is an abnormal and excessive development of tissue, arises. Once the original causative factor is eliminated, the growth of a neoplasm persists in an abnormal manner and usually progresses to a mass, at which point it may be classified as a tumor. The development of this entity lacks coordination with the growth of the adjacent healthy tissue. Moreover, neoplasms may be classified into four main groups: malignant neoplasms, benign neoplasms, in situ neoplasms, and neoplasms with unpredictable or unidentified activity. The target group consists of malignant neoplasms, which constitute the primary emphasis of oncology and are colloquially known as malignancies. Frequently, cells undergo an abnormal pattern of development, such as metaplasia or dysplasia, prior to the abnormal growth of tissue, referred to as neoplasia. Nevertheless, metaplasia or dysplasia can also manifest in other diseases and does not inevitably differentiate into neoplasia.

Infrared Radiation (IR):

Infrared radiation (IR) or electromagnetic radiation (EMR): is electromagnetic radiation with wavelengths longer than visible light and smaller than microwave radiation[10] as shown in the figure below:

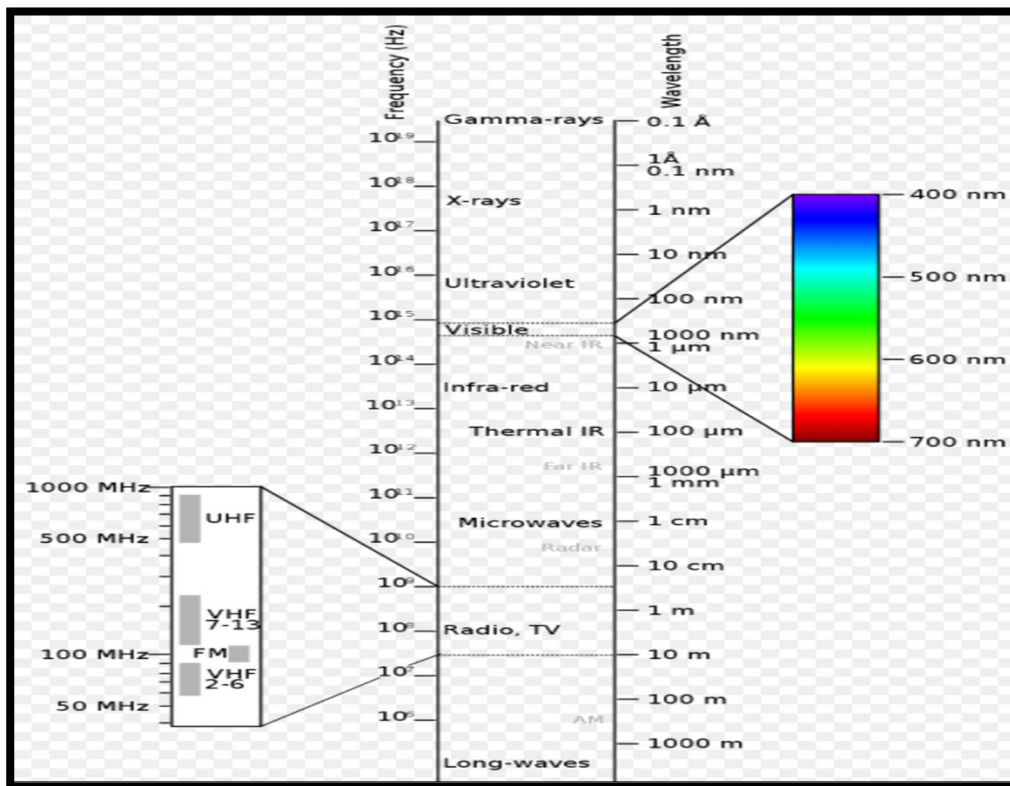


Figure (1) electromagnetic spectrum

Therefore, it possesses wavelengths ranging from around 1000 nanometers (300 GHz) to 700 nanometers (430 THz), which corresponds to the nominal red limit of the visible spectrum, rendering it imperceptible to the human visual system. Black-body radiation at infrared wavelengths is almost entirely emitted by objects at and around room temperature [11]. As a kind of electromagnetic radiation, it propagates forward as both energy and

momentum, exhibiting properties of both a wave and a particle (photon).

Reasons of IR Selection:

Infrared radiation is selected for imaging due to several factors. Firstly, the human body serves as the source of radiation, that eliminating the need for any external source of radiation, whether ionizing or non-ionizing. Secondly, there is no physical contact between the human body and the detector [12]. Thirdly, it is a non-invasive technique also it is cost-effective and easily accessible. Lastly, it accurately generates functional images known as thermograms.

Breast Anatomy:

The female breast is composed of the base, apex, and tail. The Base, which usually spans from the sternum to the mid-axillary line and the second to sixth ribs, passes from the sagittal axis towards the lateral side [5]. This muscle, called the pectoralis major, comprises two-thirds of its base. One-third of the muscle is situated on the inferior lateral aspect of the external oblique and serratus anterior muscles. It traverses the axilla using a surgical technique known as the axillary tail or axillary process. The fourth intercostal gap is the anatomical location of the conical-shaped nipple. In contrast, the round, dark pink, brownish-colored region of skin that encloses the nipple is known as the areola. No adipose tissue is present in the subcutaneous tissues of the areola or nipple.

Unenclosed sweat glands have undergone a transformation into mammary glandettes. Embedded inside the subcutaneous adipose tissue, these structures consist of ten to fifteen lobes, each containing several lobules. Thin fibrous threads called Ligaments of Cooper connect the deep fascia of the pectoralis major with the epidermis. The lobes and deep fascia are separated by the retro-mammary gap (RMB). Where The lobes and lobules are separated by fibrous structures called "ligaments of Cooper" and interlobar and metalobular adipose tissue. Furthermore, the nipples possess a range of 15 to 20 lactiferous ducts that terminate through an equivalent number of openings located at the top of the structure. The arteries who correspond to the veins include the lateral thoracic artery, intercostal arteries, perforating branches, and mammary branches of the internal thoracic (internal mammary) artery. Furthermore, the circular venous plexus, situated around the base of the nipple, drains the axillary and internal thoracic veins. Upon the convergence of the arteries of the pectoral (anterior), sub-scapular (posterior), brachial (lateral), central, and apical groups of axillary lymph nodes, the subclavian lymph trunk is established.

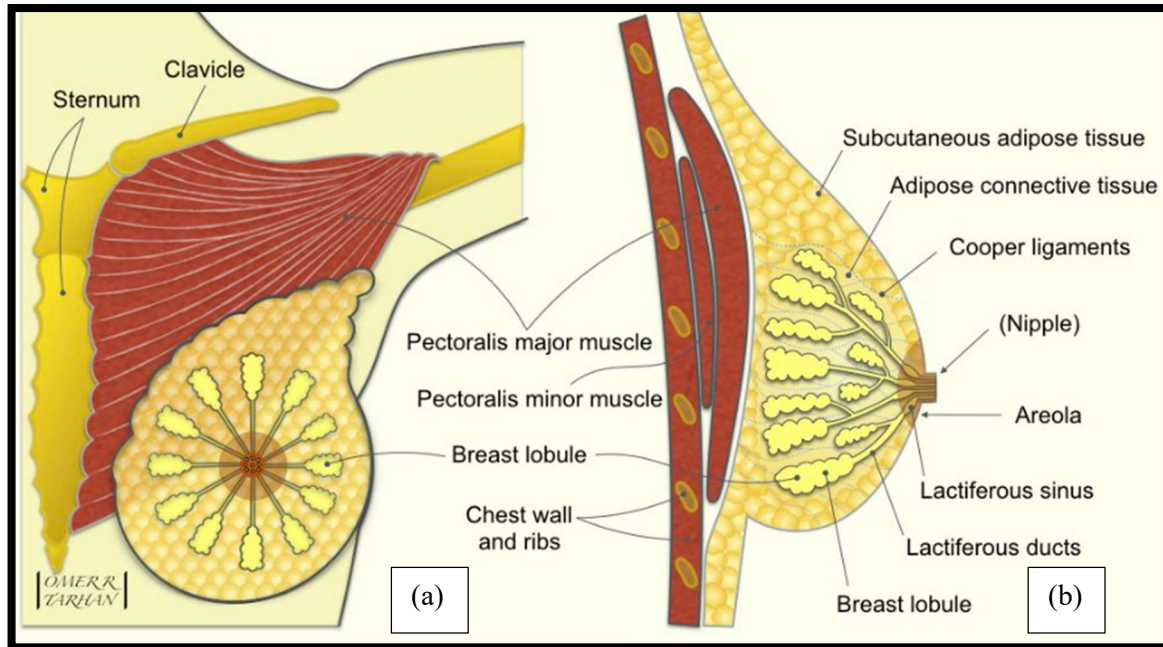


Figure (2) (a) section of front view of breast anatomy (left breast) (b) Section of the breast: (left) inner structure of the mammary gland.

Materials and procedure:

Before starting imaging, there are several factors must be considered first:

- i. IR imaging depends on the interesting band of detection where the IR detector covers the short portion of wavelengths of IR wavelengths range. So the purpose of imaging is to indicate the suitable band.

For human body infrared radiation, the suitable band extends from (2000 nm to 20,000 nm). The used IR detector features are shown below:

No.	Item	Specification
1.	Sensor	Uncooled infrared focal plane
2.	Spectral Range	(8-14 μ m)
3.	Resolution	256x192
4.	Pixel Size	12 μ m
5.	NETD	≤ 50 mK at 25 $^{\circ}$
6.	Frame Rate	≤ 25 Hz
7.	Image Output	10 bit/14 bit
8.	Lens	thermalized

Figure (3) IR detector properties

- ii. From the ethics side the patient must have a brief information about IR radiation and its technique then get his permission for imaging as shown below:

Patient information

Name:
Gender:
Age:
Time from last period:
Status:
Number of children:
Breast feeding:
Nipple Discharge:
Patient code:
Height:
Weight:
Disease condition:
Other modality:
Color of skin:
Family History:

Notes:

Figure (4) patient information

- iii. Imaging System:
Components of the system include an IR Camera which consists of an IR detector with an IR transparent filter plus black background as shown below:

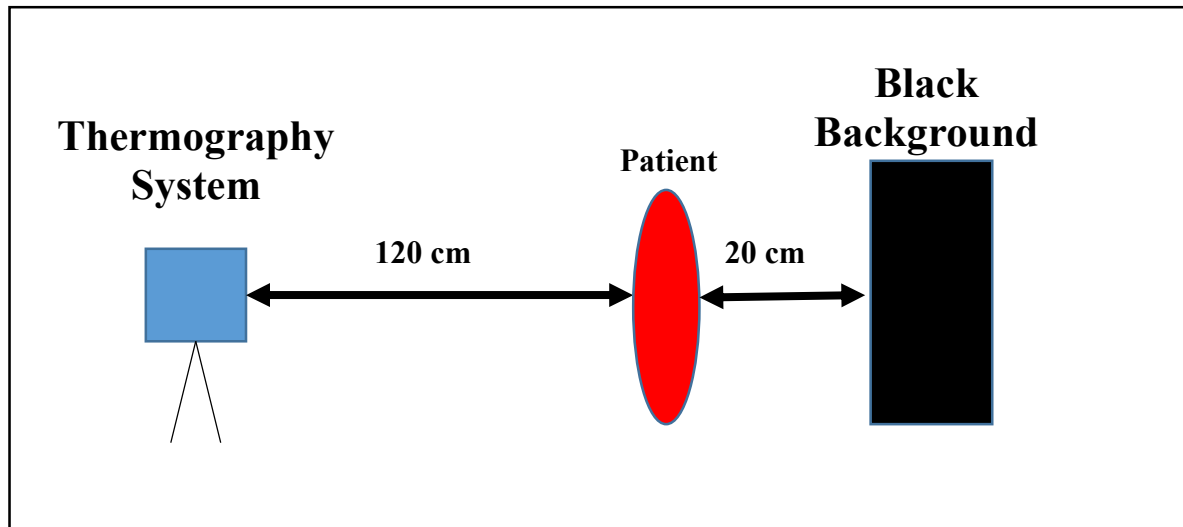


Figure (5) imaging alignment

iiii. The conditions of imaging [13] are very important to get good thermograms where the IR radiation is weak and affected by the environment such as the ambient temperature and humidity and light (sunlight and lamp lights), also the patient must be calm and not exhausted or at a period time.

2.1 procedure:

The patient must remove her clothes and rest for at least 5 minutes before imaging, and it is preferred that a female operator do this.

Results:

After Imaging several cases the results are shown:

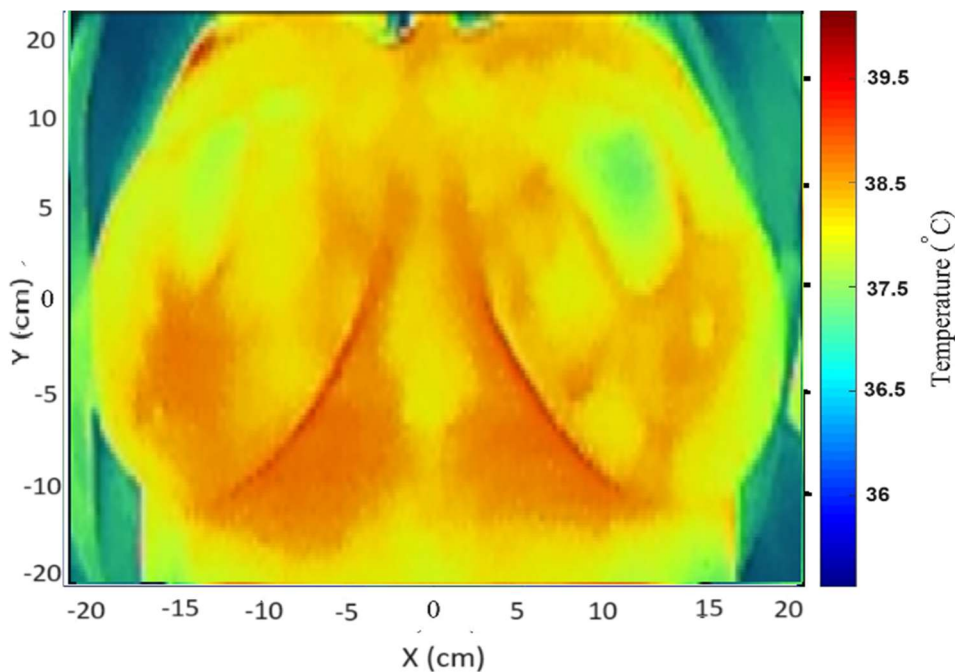


Figure (6) Thermogram of the case study

In the case study thermogram in Figure (6) the volunteer refused to have a total disrobing and made the imaging process quickly resulting in showing heat regions on the breast organ but the maximum recorded temperature around the areola is about (37.3°C) which is accepted temperature as well as thermogram Still the symmetry of the breast's thermal patterns and sizes that tells a normal condition.

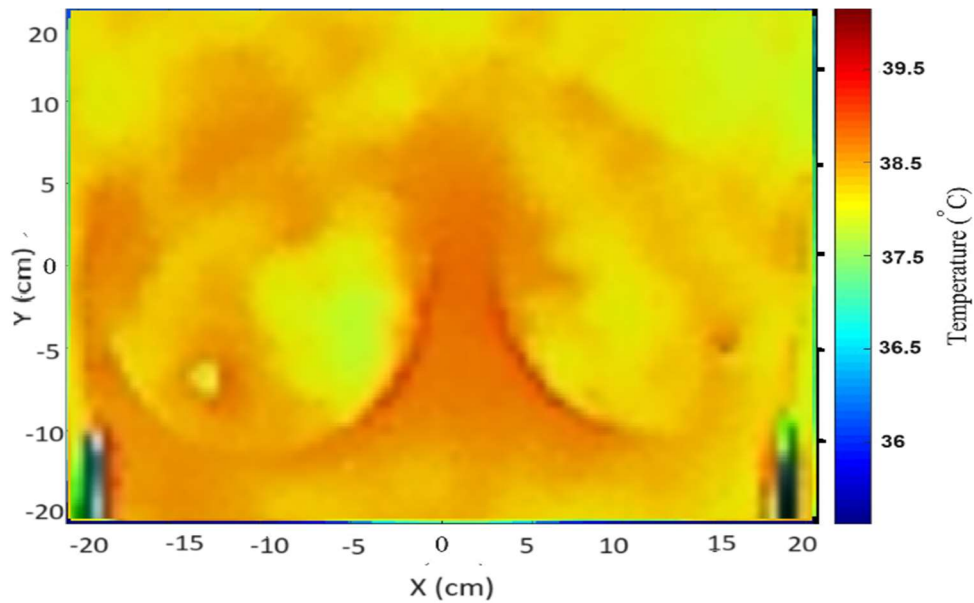


Figure (7) Thermogram of the case (m)

In the figure above the patient has pain in the right breast and she did mammography and a thermogram at the same time. the thermogram shows the symmetry of the breast in size and symmetry in thermal pattern as a negative indicator of breast cancer and the mammography confirmed the same result.

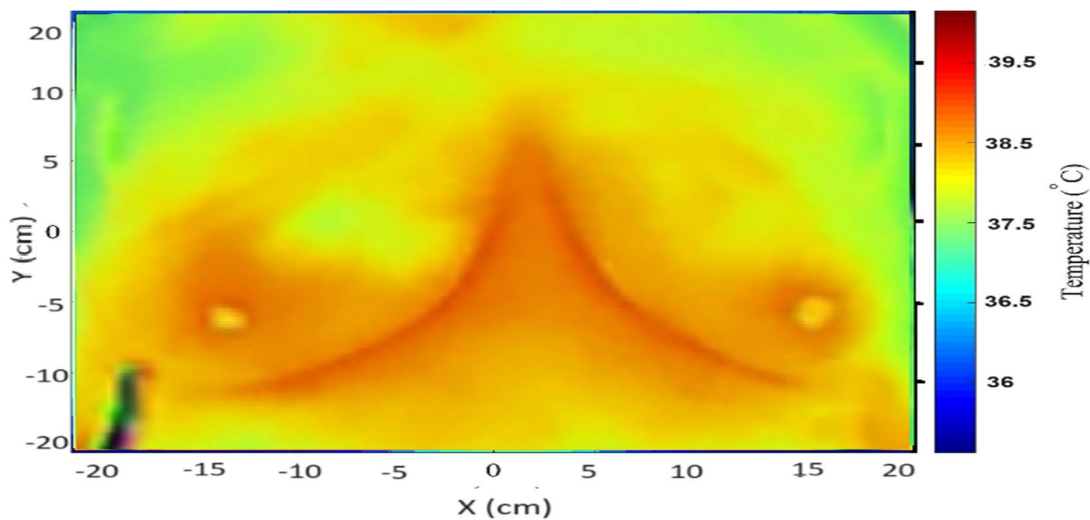


Figure (8) Thermogram of the case (y)

The figure above thermogram shows the asymmetry of the breast thermal pattern and symmetry in size which

can be considered a positive indicator of breast cancer (central area of the right breast) which confirmed by mammography too.

Conclusion & Discussion:

Thermography is a promising complementary diagnostic tool [14] that can be used for subcutaneous cancers and it can be carried out in oncology as a reliable technique due to many factors such as the utility of IR Imaging systems recent can scan over the bandwidth of wavelengths instead of a single wavelength and the accurate analysis of the resulted images instead of colored images only and the comparison between the results of the IR Imaging and conventional modalities results [15]. In addition, it can be used to make a Medical history of selected patients from the diagnosis to the final cure. Thermography overcame many limitations that occurred in other modalities such as the dense breast, hazards of radiation, age limitations, mutation probability (Mammography limitations), or Isotopes effect on the patient's body (PET-CT, and SPECT-CT) as well as the high cost [16] [17] [18]. Still, thermography has limitations too such as flat chest and partial mastectomy, and female period effects on the female's body that result in false positive thermograms [19] [20].

References:

1. Freddie Bray et al., "Global cancer statistics 2022: GLOBOCAN estimates of incidence and mortality worldwide for 36 cancers in 185 countries", *CA: A Cancer Journal for Clinicians*, Volume74, Issue3, Pp (229-263), May/June 2024.
2. Al-Nakhli, Hani H et al. "The use of thermal infra-red imaging to detect delayed onset muscle soreness." *Journal of visualized experiments : JoVE*, 59 3551. 22 Jan. 2012, doi:10.3791/3551
3. Rich, Preston B et al. "Infrared thermography: a rapid, portable, and accurate technique to detect experimental pneumothorax." *The Journal of surgical research* vol. 120,2 (2004): 163-70. doi:10.1016/j.jss.2004.02.026
4. Huang, Chi-Lun et al. "The application of infrared thermography in evaluation of patients at high risk for lower extremity peripheral arterial disease." *Journal of vascular surgery* vol. 54,4 (2011): 1074-80. doi:10.1016/j.jvs.2011.03.287
5. Zaproudina, Nina et al. "Plantar infrared thermography measurements and low back pain intensity." *Journal of manipulative and physiological therapeutics* vol. 29,3 (2006): 219-23. doi:10.1016/j.jmpt.2006.01.003
6. Arora, Nimmi et al. "Effectiveness of a noninvasive digital infrared thermal imaging system in the detection of breast cancer." *American journal of surgery* vol. 196,4 (2008): 523-6. doi:10.1016/j.amjsurg.2008.06.015
7. Côte, Ana Carolina et al. "Infrared thermography study as a complementary method of screening and prevention of muscle injuries: pilot study." *BMJ open sport & exercise medicine* vol. 5,1 e000431. 3 Jan. 2019, doi:10.1136/bmjsem-2018-000431
8. Côte, Ana Carolina et al. "Infrared thermography study as a complementary method of screening and prevention of muscle injuries: pilot study." *BMJ open sport & exercise medicine* vol. 5,1 e000431. 3 Jan. 2019, doi:10.1136/bmjsem-2018-000431
9. Švantner, Michal et al. "Statistical Study on Human Temperature Measurement by Infrared Thermography." *Sensors (Basel, Switzerland)* vol. 22,21 8395. 1 Nov. 2022, doi:10.3390/s22218395
10. Brewer, Noel T et al. "Systematic review: the long-term effects of false-positive mammograms." *Annals of internal medicine* vol. 146,7 (2007): 502-10. doi:10.7326/0003-4819-146-7-200704030-00006
11. Hildebrandt, Carolin et al. "An overview of recent application of medical infrared thermography in sports medicine in Austria." *Sensors (Basel, Switzerland)* vol. 10,5 (2010): 4700-15. doi:10.3390/s100504700

12. Zaproudina, Nina et al. "Reproducibility of infrared thermography measurements in healthy individuals." *Physiological measurement* vol. 29,4 (2008): 515-24. doi:10.1088/0967-3334/29/4/007
13. Huggins, J, and Mark Rakobowchuk. "Utility of lacrimal caruncle infrared thermography when monitoring alterations in autonomic activity in healthy humans." *European journal of applied physiology* vol. 119,2 (2019): 531-538. doi:10.1007/s00421-018-4041-6
14. Vardasca et al., "Integrating medical thermography on a RIS using DICOM standard ", *THERMOLOGY INTERNATIONAL*, Vol.3,2012.
15. Niu, H H et al. "Thermal symmetry of skin temperature: normative data of normal subjects in Taiwan." *Zhonghua yi xue za zhi = Chinese medical journal; Free China ed* vol. 64,8 (2001): 459-68.
16. Kolosovas-Machuca, Eleazar Samuel, and Francisco Javier González. "Distribution of skin temperature in Mexican children." *Skin research and technology : official journal of International Society for Bioengineering and the Skin (ISBS) [and] International Society for Digital Imaging of Skin (ISDIS) [and] International Society for Skin Imaging (ISSI)* vol. 17,3 (2011): 326-31. doi:10.1111/j.1600-0846.2011.00501.x
17. Jorge, Joao et al. "Non-Contact Assessment of Peripheral Artery Haemodynamics Using Infrared Video Thermography." *IEEE transactions on bio-medical engineering* vol. 68,1 (2021): 276-288. doi:10.1109/TBME.2020.2999539
18. Fernandes, Alex de Andrade et al. "Regional Skin Temperature Response to Moderate Aerobic Exercise Measured by Infrared Thermography." *Asian journal of sports medicine* vol. 7,1 e29243. 1 Mar. 2016, doi:10.5812/asjrm.29243
19. Magalhaes, C et al. "Recent use of medical infrared thermography in skin neoplasms." *Skin research and technology : official journal of International Society for Bioengineering and the Skin (ISBS) [and] International Society for Digital Imaging of Skin (ISDIS) [and] International Society for Skin Imaging (ISSI)* vol. 24,4 (2018): 587-591. doi:10.1111/srt.12469
20. Ring, E F J, and K Ammer. "Infrared thermal imaging in medicine." *Physiological measurement* vol. 33,3 (2012): R33-46. doi:10.1088/0967-3334/33/3/R33