

## The Surgical Management Of Cervical Spine Tuberculosis: Functional Result Study

**Dr.Prabhakaran AK., Dr.Yeshwanth Subash.**

<sup>1</sup>Department of Orthopaedics Saveetha Medical College and Hospital Saveetha Institute of Medical and Technical Sciences, Saveetha University, Thandalam, Chennai – 602105 Tamilnadu, India.

<sup>2</sup>Corresponding author: D.N.B (ORTHO),M.N.A.M.S, Professor, Department of Orthopaedics Saveetha Medical College and Hospital Saveetha Institute of Medical and Technical Sciences, Saveetha University, Thandalam, Chennai – 602105

---

Cite this paper as: Prabhakaran AK.,Yeshwanth Subash. (2024) The Surgical Management Of Cervical Spine Tuberculosis: Functional Result Study. *Frontiers in Health Informatics*, 13 (3), 8334-8345

---

### **ABSTRACT:**

**INTRODUCTION:** The incidence of CSTB (Cervical Spinal Tuberculosis) incidence is 2%–12%. The condition can cause cervical instability, neurological difficulties, invasion of the vertebral artery as well as nerve root, subtle onset, tiny cervical spinal canal cross-sectional diameter, medication resistance, and delayed diagnosis. The goal of our research is to assess the functional result following ACDF (Anterior Cervical Disc Fusion).

**MATERIALS AND METHODS:** This is retrospective research involving 20 patients with cervical spine tuberculosis aged 18-70 years. The study was conducted at Saveetha Medical College in Chennai, India, between May 2021 and May 2023. Individuals receiving anti-TB medication for cervical spine tuberculosis who had not previously had surgery, patients whose condition did not improve with conservative treatment, and patients whose neurological deficits were getting worse were all included in the study. Patients were checked every three, six, ten, fourteen, three, and six months.

**RESULT:** The study had a majority of male participants, accounting for 60%. A higher number of patients were aged between 21 and 30 (6 patients). 10 patients had a VAS score- 8, 2 patients had a VAS score- 9, whereas the rest had a VAS score- 7. All patients displayed elevated ESR and CRP levels before surgery. ESR and CRP levels normalized after the operation. No patients were lost to follow-up throughout the study period.

**CONCLUSION:** Cervical spine TB should therefore be identified early and treated quickly. The trans-oral core needle biopsy can be used to obtain tissue for upper CSTB diagnosis. The posterior technique alone can adequately handle the majority of atlantoaxial CSTB. The posterior stabilization of atlanto-axial CSTB depends on the integrity of the C1 and C2 pedicles and lateral masses.

**Keywords:** Cervical spine tuberculosis; anterior cervical disc fusion; atlanto-axial tuberculosis; cervical instability

### **INTRODUCTION**

One of the world's most deadly infectious diseases is still tuberculosis. Skeletal tuberculosis makes up 1-3%, while spinal TB accounts for 50% of skeletal TB. Spinal tuberculosis makes up only 1% of all tuberculosis cases, although its prevalence is growing [1]. Cervical spinal tuberculosis makes up just 3-5% of all spinal tuberculosis cases [2-5], making it less common than thoracolumbar tuberculosis.

The condition can cause neurological difficulties, invasion of the vertebral artery and nerve root, cervical instability, subtle onset, tiny cervical spinal canal cross-sectional diameter, medication resistance, and delayed diagnosis. SCS-TB (Subaxial Cervical Spinal Tuberculosis) is always linked with early cervical kyphosis and more severe neurological dysfunction. [6,7]

Cervical spine TB should therefore be identified early & treated quickly. Because of the prevalence of HIV and the advent of treatment resistance, even though the efficacy of anti-TB drugs has significantly improved, it is still difficult to completely eradicate tuberculosis [8]. Patients with cervical spine TB who have a spinal

deformity, substantial neurological dysfunction, and have not responded to conservative treatment must have surgery.[9] The goal of our research is to assess the functional result following ACDF.

### **MATERIALS AND METHODS:**

This is prospective research conducted on 20 patients with cervical spine tuberculosis aged 18-70 years. The research was carried out at Saveetha Medical College in Chennai, India, from May 2021 to May 2023. The ethics committee of the institution approved the research. The research involved patients with TB affecting the cervical spine, either in the presence or absence of additional lesions. It also included patients with cervical spine TB who were undergoing anti-TB treatment but had not undergone surgery before, as well as patients with cervical spine TB who were admitted due to lack of improvement with conservative treatment or worsening neurological deficits. Patients who had prior cervical spine tuberculosis surgery and individuals aged below 18 or above 70 were not included in the study. All patients admitted to the institute with limb weakness, neck pain, and neck stiffness, underwent thorough clinical and radiological examinations upon admission. Patients were classified according to ASIA grading (Figure 1, Figure 2) (16) and visual analogue score (Figure 3). Written consent was obtained from the patient's attendants after informing them about the surgery and potential complications.

Every patient had baseline routine radiological and hematological investigations done. All patients with atlantoaxial tuberculosis were treated using the posterior approach only after a CT scan verified that the C1 and C2 pedicles were intact. The two primary methods for treating atlantoaxial tuberculosis are trans-oral and retropharyngeal exposures. According to preoperative nasopharyngeal culture & sensitivity studies, prophylactic antibiotics are administered for the trans-oral technique both immediately before surgery and 72 hours afterward. A vertical incision is made through the longus colli muscle, constrictors, and posterior pharyngeal mucosa utilizing the anterior arch of the atlas as a milestone. The anterolateral retropharyngeal method involves partially cutting the sternocleidomastoid & moving laterally as well as posterior to the carotid sheath to expose the upper cervical spine. On the other hand, the antero-medial retropharyngeal method utilizes the interval medial (anterior) to the carotid sheath. The most common method for treating tuberculosis in the subaxial region is the antero-medial approach, which uses the space between the tracheo-esophageal complex and strap muscles medially and the sternocleidomastoid laterally. Para spinal muscles were retracted and the lamina of cervical vertebrae was visualized. 3.5mm and 4.5 mm pedicle screws were placed and checked under C arm guidance. Thorough wide compression and pus if present drained and sent for culture sensitivity, histopathology, and CB NAAT. A corpectomy was done if required and 100 or 150mm rods and cage were inserted. The final tightening of screws was done. A thorough wound wash was given. Sterile dressing was done.

On the first postoperative day, patients were permitted to lie down, on the second, to sit, and on the third, to stand or move around. Day 12 saw the removal of the sutures. Patients with neural deficits underwent immediate initiation of active rehabilitation. In patients whose bone quality was satisfactory, neither bracing nor cast immobilization was utilized. Patients received oral HREZ (pyrazinamide, rifampicin, isoniazid, ethambutol) chemotherapy for three months following surgery. They subsequently underwent 9–12 months of HRE (ethambutol, isoniazid, rifampicin,) chemotherapy regimens. Every patient received instruction on the significance of taking prescription drugs exactly as directed. The absence of abnormal motion, bony trabecular bridges, loss of correction, and instrumentation failure were all indicators of a successful fusion procedure. The clinical response, blood test normalization (CRP and ESR), along radiographic healing indicators were employed to resolve when to stop the course of treatment. Following treatment, all individuals were checked on every three months for the 1<sup>st</sup> three months, and then every month for the final twelve months. ESR as well as CRP readings, physical & radiographic exams, along a neurological status evaluation were used to monitor the patients.

### **RESULT:**

Twenty patients total participated in our study, and each patient received routine follow-up. This study had a 60% male preponderance [Figure 4]. With a mean age of 38, the age group spans from 18 to 70 years old. Six patients, or more, belonged to the age group of 21 to 30. Ten patients had a VAS score of eight, two had a

score of nine, and the remaining two had a score of seven [Figure 5]. In the majority of the patients (10%) and grade B (50%) neurological deficits were present in all of the patients. Before surgery, all of the patients had elevated CRP and ESR levels. After surgery, the patient's ESR along with CRP levels back to normal. Throughout the research period, no patients were lost to follow-up.

Following surgery, the mean ESR was 6.36 mm/h (interval 2–12mm/h) as well as the mean CRP was 3.8mg/dl (interval 2.0–6.0mg/dL) (P-value). Before surgery, all patients had elevated ESR and CRP readings, which progressively dropped and eventually returned to normal levels nine months later. At the final follow-up, VAS scores dropped considerably with a mean preoperative score of 7.7 falling to a mean of 2.2 (P value <0.05) [Figure 6].

The kyphotic deformity in the sub-axial CSTB ranged from 7.45o to 27.41 with a mean of 17.65. In this study (5 patients), C1–C2 CSTB was predominant overall. In the subaxial cervical spine, all levels are equally likely to be involved; four patients' vertebral levels, from C7 to D1, are affected. Ten patients had involvement of at least two vertebral bodies, while four patients only had involvement of one vertebral body. The disease process primarily destroyed one body in five patients and up to three bodies in two patients.

16 patients (or 80%) out of the 20 had positive results from the Gene Xpert study. In three of the seven atlantoaxial TB patients in this study who showed severe instability and consequent neurological impairment, we performed posterior stabilization. Patients with the anterior disease as well as no gross instability underwent anterior surgical practices such as anterior stabilization with screws and plates via retropharyngeal abscess drainage (1 patient), submandibular approach (1 patient), and trans oral core needle biopsy (2 patients).

1 patient in grade B progressed to grade E, six patients in grade B advanced to grade D, six patients in grade C improved to grade E, whereas one patient in grade D upgraded to grade E at the final follow-up examination.

An average of 20.5 months were spent following the patients (range: 15–27 months). After surgery, the kyphotic Cobb angles decreased from a mean of 24.4 (interval 8.2–24.4) to 0.5 (range -4 to 4) [Figure 7]. The mean Cobb angle of kyphosis during the most recent follow-up was 1.4 (interval -2 to 10), with a P value <0.05. To evaluate the bony fusion both after surgery and during the follow-up, a CT scan was performed. Nineteen patients (95%) out of the twenty who had a full follow-up demonstrated solid bony fusion [Table 1]. During the most recent follow-up visit, bony fusion could not be shown in one patient. This patient experienced a screw breakage.

Just one of the twelve sub-axial CSTB patients treated with instrumented fusion continued to experience pain at the graft site. A superficial infection was treated with the right antibiotics in 1 individual with subaxial CSTB who had anterior debridement plate fixation, and grafting of bone. Even though the patient had undergone C1C2 fusion without any symptoms, radiography revealed a complication in the form of a broken screw [Figure 8].

## DISCUSSION:

TB of the cervical spine is an unusual condition with unique clinical features and therapeutic difficulties. 4% to 12% is the reported incidence of CSTB [10]. Because of the low incidence of this disease, literature on clinical studies of it is relatively scarce. Owing to its intricate structure, the cervical spine is vulnerable to both severe neurological damage and devastating deformities associated with late-onset myelopathy. Three separate areas can be used to manage cervical spine tuberculosis: the cervico-thoracic junction, the atlanto axial complex, and the sub-axial cervical spine (mid-cervical). Very rare (0.3–1% of cases of tuberculosis overall) is atlantoaxial tuberculosis [11]. Plaster immobilization, Halo-device fixation, & other conservative techniques were used to treat upper cervical spine injuries without a neurological deficiency as well as severe instability. Surgical management for upper cervical tuberculosis patients has steadily grown due to the introduction of devices for internal fixation as well as procedures for spinal surgery, improved knowledge of atlantoaxial regional anatomy, and advancements in radiological evaluation.

A prior surgical procedure is used to treat tuberculous lesions that commonly affect the atlanto-axial joint, which is situated in the anterior region of the vertebral body. Direct decompression, Direct lesion removal, and the elimination of spinal cord compression are the benefits of these procedures; however, because of the anatomy of the atlantoaxial joint, injury to the anterior column of the atlantoaxial joint, and the absence of a reliable internal

fixation technique, achieving stability following focal debridement and bone graft fusion is problematic to accomplish anteriorly.

The authors Zhang et al. [12] explained a 1-stage procedure that reduced the amount of blood loss as well as the amount of time spent under anaesthesia. This procedure included posterior instrumentation, posterior debridement, and short-segment fusion. The posterior surgical technique had a low incidence of complications due to the straightforward nature of its anatomy. Patients with chronic squamous cell tuberculosis who underwent posterior radical debridement, decompression, along with internal fixation demonstrated favourable outcomes, as per Wang et al.'s findings from 2014 (39). Mandavia et al. [13] have proposed the posterior cervical approach as a safe as well as efficacious treatment option for patients suffering from cervical tuberculosis. The posterior approach may seem less complex at the cervico-thoracic junction because the anterior region houses the sternum, ribs, clavicle, major arteries, nerves, and thoracic duct. There is, however, no benefit to this as the injury is restricted to the anterior vertebral bodies. As a result, most people agree with the anterior approach. Patients with regional kyphosis brought on by bone loss typically appear with cervico-thoracic tuberculosis. Therefore, it is crucial to tailor a specific surgical strategy depending on the lesions' locations to maximize patient safety and achieve the best possible exposure.

The biomechanical characteristics of the cervico-thoracic junction are extremely complex because it is a zone of transition from the highly mobile cervical spine to the less mobile thoracic spine. Because of the forces operating in this area, global stabilization is necessary to keep the spine in its proper alignment. Following HPE & Gene Xpert study confirmation of the diagnosis, anti-tubercular medication was initiated for all patients. The length of time the ATT medication was administered depended on the patient's reaction, which was tracked by clinicoradiological results and serial laboratory investigations (ESR, CRP). ATT lasted, on average, between nine and twelve months.

In all cases with atlantoaxial tuberculosis, a thorough radiographic evaluation is essential, primarily to evaluate the integrity of the axis pedicles and atlas lateral masses, the structures that allow for posterior instrumentation. If the lateral masses of the atlas or the pedicle of the axis are destroyed, the posterior instrumentation needs to be extended both distally (to the subaxial spine) and proximally (to the occiput). The best way to extract diseased tissue from lesions of the anterior structures of the atlantoaxial articulation for Gene Xpert & histological analysis is by trans oral core needle biopsy.

Transoral core needle biopsy was performed on two of our study's atlantoaxial tuberculosis patients to obtain tissue for diagnosis. Hassan [14] described the results of sixteen patients who underwent 1-stage anterior debridement, bone grafting fusion, along with H-plate fixation due to lower cervical spine TB with neurological sequelae or intolerable kyphosis. According to HE et al. [15], patients with lower cervical tuberculosis can benefit from safe and efficient treatments such as decompression, anterior debridement, bone grafting, as well as instrumentation that also have positive clinical and radiologic results. In this study, the anterior instrumented fusion patients had favourable outcomes. This was consistent with the research done by HE et al. and Hassan et al.

N. Mao et al. [16] showed that in patients with kyphosis as well as cervical tuberculosis, one-stage anterior debridement, internal fixation, as well as bone grafting can successfully decompress the nerve, remove lesions, rectify kyphosis, and alleviate discomfort. Five of the 11 patients in this study with subaxial CSTB who had less than two vertebral involvements had anterior approach surgery, which produced satisfactory results in all of them.

Three patients with two or more vertebral alterations had a combined anterior repair and posterior stabilization. This was comparable to Xin Hua Yin et al.'s study [17], which proposed that individuals with multilayer involvement require anterior debridement. If more than two consecutive vertebrae were seriously injured, a combined anterior as well as posterior methodology was necessary, especially in patients with severe kyphosis or in the pediatric age group.

Our results are in contrast with those of Koptan et al. [18], who discovered that the cage-using group had improved kyphosis correction and a better sagittal profile than the tri-cortical iliac bone grafting group. Reduction of graft-associated problems was achieved by adding anterior plating to the anterior reconstruction (bone graft/mesh cage). Although there were significant differences in the results between using a mesh cage or tri-cortical bone graft for anterior column reconstruction, Koptan et al. found that using titanium mesh cages along

with bone grafting for cervical tuberculosis after anterior debridement improved neck pain along with corrected local kyphosis.[19]

**CONCLUSION:**

With the help of this study, we were able to ultimately decide on the treatment of cervical spine TB. Most cases of atlanto-axial CSTB can be successfully treated with just the posterior technique. Tissue for an upper CSTB diagnosis can be obtained via a trans oral core needle biopsy. The integrity of the C1 & C2 pedicles as well as the lateral masses is necessary for the posterior stabilization of atlanto-axial CSTB. The instrumentation needs to be extended to the sub-axial spine and the occipital region if a tuberculous lesion develops in the pedicles of C2 or the lateral masses of C1, respectively. Depending on where the tuberculous lesion is located in atlanto-axial spine TB, the anterior approach may be employed.

Acknowledgements

Funding: None

Conflict of interest: None declared

Ethical approval: Not required

**FIGURES AND TABLES**

Figure 1 ASIA grading system

**ASIA** INTERNATIONAL STANDARDS FOR NEUROLOGICAL CLASSIFICATION OF SPINAL CORD INJURY (ISNCSCI) **ISCOS**

Patient Name: \_\_\_\_\_ Date/Time of Exam: \_\_\_\_\_  
 Examiner Name: \_\_\_\_\_ Signature: \_\_\_\_\_

**RIGHT** **MOTOR** **KEY MUSCLES** **SENSORY** **KEY SENSORY POINTS** **LEFT** **MOTOR** **KEY MUSCLES** **SENSORY** **KEY SENSORY POINTS**

**RIGHT** **MOTOR** **KEY MUSCLES** **SENSORY** **KEY SENSORY POINTS** **LEFT** **MOTOR** **KEY MUSCLES** **SENSORY** **KEY SENSORY POINTS**

**UUR** (Upper Extremity Right) **LER** (Lower Extremity Right) **UEL** (Upper Extremity Left) **LEL** (Lower Extremity Left)

**RIGHT TOTALS** (MAXIMUM) **LEFT TOTALS** (MAXIMUM)

**MOTOR SUBSCORES** **SENSORY SUBSCORES**

**NEUROLOGICAL LEVELS** **3. NEUROLOGICAL LEVEL OF INJURY (NLI)** **4. COMPLETE OR INCOMPLETE?** **5. ASIA IMPAIRMENT SCALE (AIS)** **6. ZONE OF PARTIAL PRESERVATION**

Page 12 **ISNCSCI Worksheet © 2019 by ASIA is licensed under CC BY-NC-ND 4.0** (see <http://creativecommons.org/licenses/by-nc-nd/4.0/>). **REV 0479**

Figure 2 showing ASIA impairment scale

ASIA Impairment Scale	
A Complete	No motor, no sensory, no sacral sparing
B Incomplete	No motor, sensory only
C Incomplete	50% of muscles LESS than grade 3 (can't raise arms or legs off bed)
D Incomplete	50% of muscles MORE than grade 3 (can raise arms or legs off bed)
E Normal	Motor and sensory function are normal

Figure 3 showing Visual analogue scale

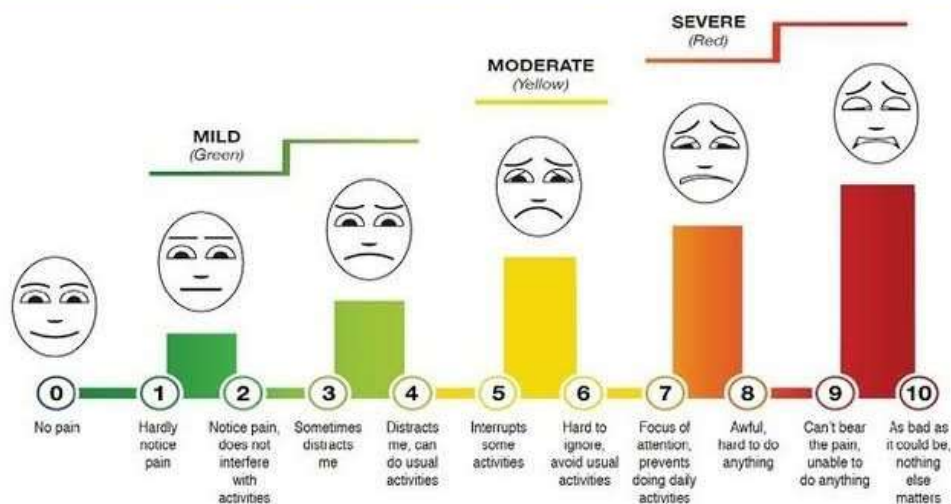


Figure 4 showing distribution of gender of patients

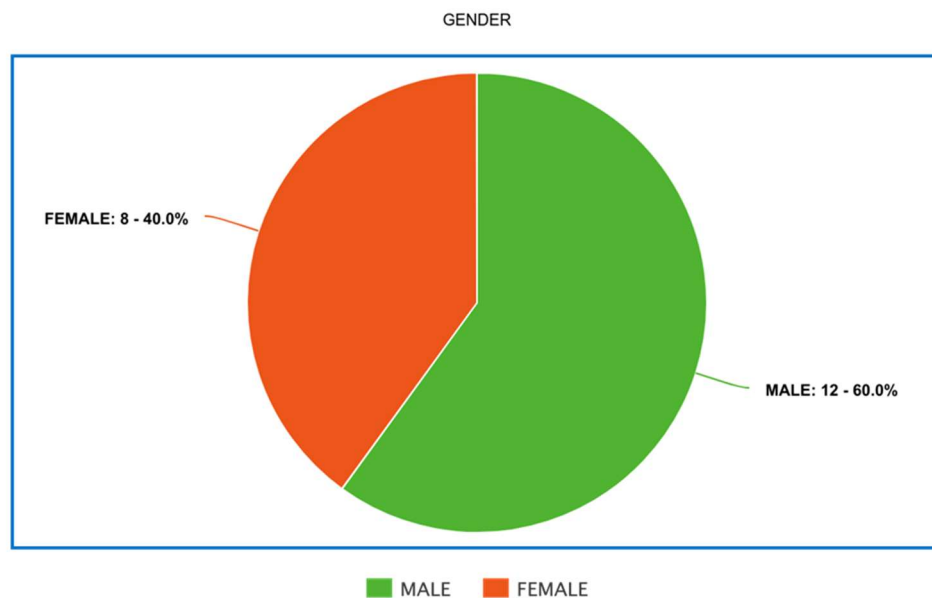


Figure 5 showing pre-operative VAS score of patients

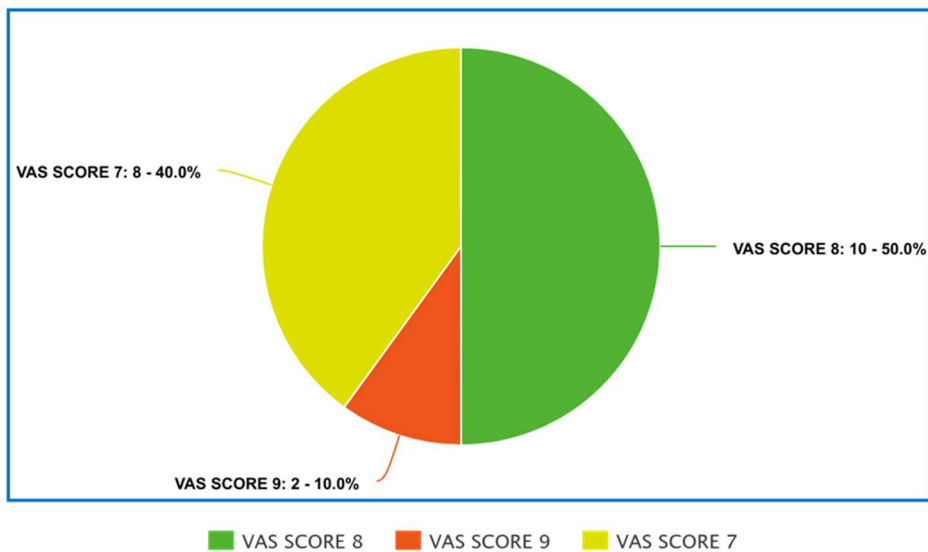


Figure 6 showing average pre and post operative VAS scores

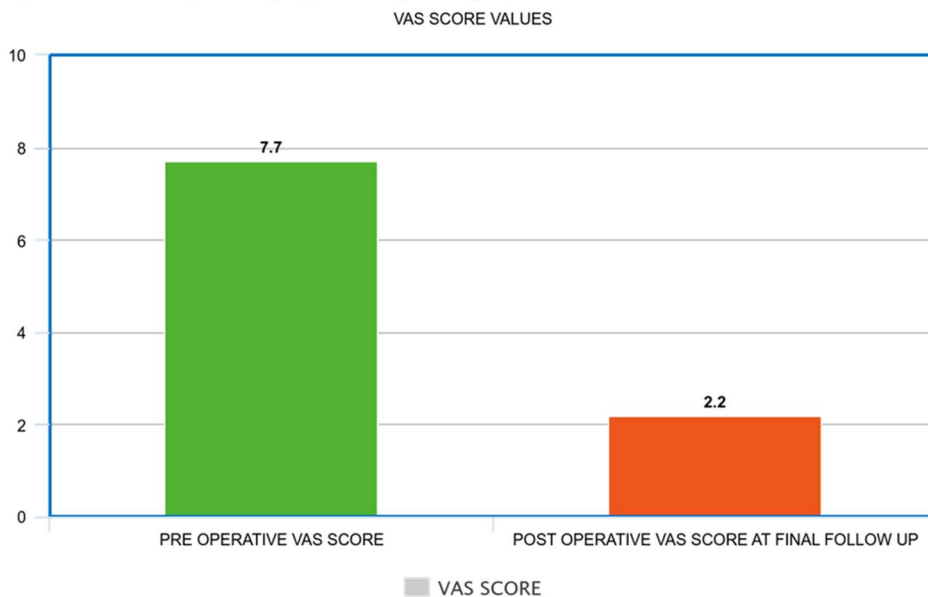


Figure 7 showing average Kyphotic angles preoperatively, immediate post operatively and at 20 months post operatively

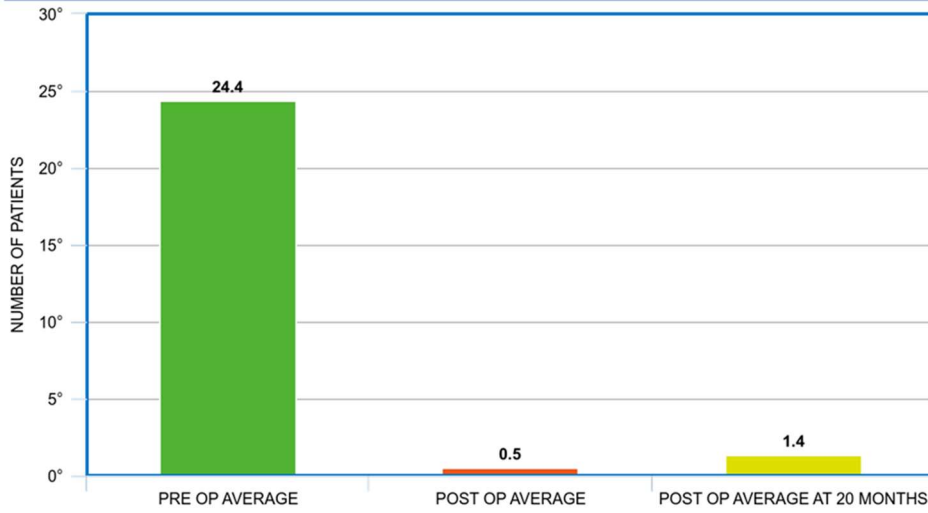


Figure 8 showing number of patients with different complication

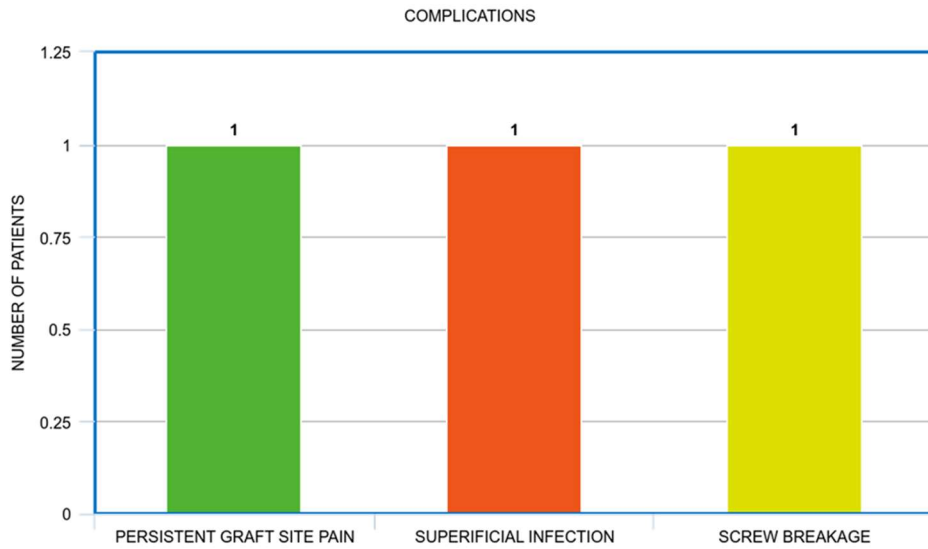


TABLE 1 showing master chart of all patients

S.O	N	AG	SE	VE	VAS	ASIA	COBB	BO	ESR(M	CRP(M	ATTGE	BIO	APPRO	CO
INDEX	RT	SCORE	SCALE	ANGLE	NY	M/HR)	G/DL)	DU	NE	PS	ACH	MP		
EB							FU		RA	XP	Y	LIC		
RA							SIO		TIO	ER	RE	ATI		
E							N		N(MT	SU		ON		
INV									ON	LT		S		
OL														

											VE					THS										
											D					)										
												PRE	PO	PR	PO	PR	PO		PR	PO	PR	PO				
												OP	ST	E	ST	E	ST		E	ST	E	ST				
												OP	OP	OP	OP	OP		OP	OP	OP						
1	32	F	C4 C5	7	2	C	E	8.2	-3	Y	50	6	15	3	8M	PO	Gra	ANTER	SIT	nulo	IOR	IV	mat	E	ous	
2	45	M	C1 C2	8	1	C	E	9.6	-2	Y	40	8	14	4	12M	PO	Gra	GLOB	SIT	nulo	AL	IV	mat	E	ous	
3	36	M	C6 C7	8	2	B	D	10	-3	Y	22	6	17	4	10M	PO	Gra	ANTER	SIT	nulo	IOR	IV	mat	E	ous	
4	44	F	C1 C2	7	3	C	E	12.4	-1	Y	34	4	15	2	8M	PO	Gra	ANTER	SIT	nulo	IOR	IV	mat	E	ous	
5	42	M	C4 C5	8	2	B	D	24.22		Y	35	6	12	4	10M	PO	Gra	GLOB	SIT	nulo	AL	IV	mat	E	ous	
6	23	F	C1 C2	7	4	D	E	20.43		Y	36	8	15	2	12M	PO	Gra	ANTER	SIT	nulo	IOR	IV	mat	E	ous	
7	18	F	C5 C6	7	2	B	E	14.24		Y	42	7	14	3	12M	NE	Gra	GLOB	GA	nulo	AL	TI	mat	VE	ous	Graf t site infe ctio n
8	67	M	C4 C5	7	2	C	D	16.24		Y	40	6	15	2	14M	PO	Gra	ANTER	SIT	nulo	IOR	IV	mat	E	ous	
9	56	F	C6 C7	8	1	B	C	12.4	-4	Y	35	4	16	5	12M	PO	Gra	GLOB	SIT	nulo	AL	IV	mat	E	ous	
10	24	M	C3 C4	8	2	B	C	17.2	-3	Y	36	5	14	6	9M	NE	Gra	GLOB	GA	nulo	AL	TI	mat	VE	ous	
11	36	F	C4 C5	8	3	C	E	11.4	-2	Y	45	2	17	4	8M	PO	Gra	ANTER	SIT	nulo	IOR	IV	mat	E	ous	

12	56	M	C1 C2	9	2	B	D	13.5-1	Y	41	6	20	4	9M	PO Gra ANTER SITnuloIOR IV mat E ous	Scre w brea kage
13	25	F	C5 C6	8	1	C	D	14.63	Y	30	4	15	5	10M	MNE Gra GLOB GA nuloAL TI mat VE ous	
14	34	M	C4 C5	9	2	B	D	15.72	Y	42	5	12	4	11M	PO Gra GLOB SITnuloAL IV mat E ous	
15	70	M	C1 C2	7	2	C	D	14.7-2	N	40	6	18	6	12M	MNE Gra POSTE GA nuloRIOR TI mat VE ous	
16	34	M	C6 C7	8	3	B	D	16.84	Y	36	10	22	2	10M	PO Gra POSTE SITnuloRIOR IV mat E ous	
17	24	M	C5 C6	7	2	C	E	24.41	Y	34	6	16	2	8M	PO Gra GLOB SITnuloAL IV mat E ous	
18	27	M	C1 C2	8	1	B	D	21.52	Y	32	10	14	4	9M	PO Gra POSTE SITnuloRIOR IV mat E ous	
19	36	M	C3 C4	7	4	B	D	23.6-2	Y	37	12	15	6	10m	PO Gra GLOB SITnuloAL IV mat E ous	
20	26	F	C6 C7	8	3	C	E	22.7-3	Y	40	6	24	4	11M	PO Gra POSTE SITnuloRIOR IV mat E ous	Sup erifi cial infe ctio n

REFERENCES

1. Polley P, Dunn R (2009) Noncontiguous spinal tuberculosis: incidence and management. *EUR Spine J* 18(8):1096–1101
2. Hsu LC, Leong JC (1984) Tuberculosis of the lower cervical spine (C2–C7). A report on 40 cases. *J Bone Joint Surg Br* 66(1):1–5
3. Garg B, Mehta N, Vatsya P (2020) Surgical strategy for correction of severe, rigid, post-tubercular cervical kyphosis: an experience of two cases. *Spine Deform* 8(4):801–807
4. Sadulla, Shaik. "Next-Generation Semiconductor Devices: Breakthroughs in Materials and Applications." *Progress in Electronics and Communication Engineering* 1.1 (2024): 13-18.
5. Turgut M (2001) Spinal tuberculosis (Pott's disease): its clinical presentation, surgical management, and outcome. A survey study on 694 patients. *Neurosurg Rev* 24(1):8–13
6. Hassan M (2003) Anterior plating for lower cervical spine tuberculosis. *Int Orthop* 27(2):73–77
7. Gowhari Shabgah, A., Abdelbasset, W.K., Sulaiman Rahman, H., Bokov, D.O., Suksatan, W., Thangavelu, L., Ahmadi, M., Malekahmadi, M., Gheibihayat, S., Gholizadeh Navashenaq, J. A comprehensive review of IL-26 to pave a new way for a profound understanding of the pathobiology of cancer, inflammatory diseases and infections. *Immunology*, 2022; 165(1): 44-60.
8. Jasim, S.A., Yumashev, A.V., Abdelbasset, W.K., Margiana, R., Markov, A., Suksatan, W., Pineda, B., Thangavelu, L., Ahmadi. Shining the light on clinical application of mesenchymal stem cell therapy in autoimmune diseases. *Stem Cell Research and Therapy*, 2022; 13 (1): 101.
9. Muralidharan, J. "Machine Learning Techniques for Anomaly Detection in Smart IoT Sensor Networks." *Journal of Wireless Sensor Networks and IoT* 1.1 (2024): 10-14.
10. Ferrer MF, Torres LG, Ramírez OA, Zarzuelo MR, Del Prado González N (2012) Tuberculosis of the spine. A systematic review of case series. *Int Orthop* 36(2):221–231
11. Huldani, H., Abdalkareem Jasim, S., Bokov, D.O., Abdelbasset, W.K., Nader Shalaby, M., Thangavelu, L., Margiana, R., Qasim, M.T. Application of extracellular vesicles derived from mesenchymal stem cells as potential therapeutic tools in autoimmune and rheumatic diseases. *International Immunopharmacology*, 2022; 106:108634.
12. Surendar, A. "Emerging Trends in Renewable Energy Technologies: An In-Depth Analysis." *Innovative Reviews in Engineering and Science* 1.1 (2024): 6-10.
13. Yin XH, He BR, Liu ZK, Hao DJ. The clinical outcomes and surgical strategy for cervical spine tuberculosis: A retrospective study in 78 cases. *Medicine (Baltimore)*. 2018 Jul;97(27):e11401.
14. Mandavia R, Fox R, Meir A. Atlantoaxial TB with paralysis: posteriorly cervical approach with good results. *JRSM Open*. 2017 Jun;8(6):2054270417697866.
15. Zhang H-Q, Lin M-Z, Guo H-B, Ge L, Wu J-H, Liu J-Y. One-stage surgical management for tuberculosis of the upper cervical spine by posterior debridement, short-segment fusion, and posterior instrumentation in children. *Eur Spine J Off Publ Eur Spine Soc Eur Spinal Deform Soc Eur Sect Cerv Spine Res Soc*. 2013 Jan;22(1):72–8.
16. Mandavia R, Fox R, Meir A. Atlantoaxial TB with paralysis: posteriorly cervical approach with good results. *JRSM Open*. 2017 Jun;8(6):2054270417697866.

17. Toualbia, Abdelatif, and Nabila Barrouk. "Blow-up Phenomena for Pseudo-Parabolic Kirchhoff Equations with Logarithmic Nonlinearity." *Results in Nonlinear Analysis*, vol. 7, no. 2, 2024, pp. 115–126.
18. Elamalki, Driss, Abdelilah Kaddar, and Nadia Beniich. "Stability of an Unemployment Model with a Non-Linear Job Creation." *Results in Nonlinear Analysis*, vol. 7, no. 2, 2024, pp. 127–139.
19. Khan, Mohammad Nazrul Islam, et al. "Geometric Properties of Submanifolds of a Riemannian Manifold in Tangent Bundles." *Results in Nonlinear Analysis*, vol. 7, no. 2, 2024, pp. 140–153.
20. Sadulla, Shaik. "A Comparative Study of Antenna Design Strategies for Millimeter-Wave Wireless Communication." *SCCTS Journal of Embedded Systems Design and Applications* 1.1 (2024): 11-15.
21. Yin XH, He BR, Liu ZK, Hao DJ. The clinical outcomes and surgical strategy for cervical spine tuberculosis: A retrospective study in 78 cases. *Medicine (Baltimore)*. 2018 Jul;97(27):e11401.
22. Koptan W, ElMiligui Y, ElSharkawi M. Single stage anterior reconstruction using titanium mesh cages in neglected kyphotic tuberculous spondylodiscitis of the cervical spine. *Eur Spine J*. 2011 Feb;20(2):308–13.
23. Rupp, R., Biering-Sørensen, F., Burns, S. P., Graves, D. E., Guest, J., Jones, L., Read, M. S., Rodriguez, G. M., Schuld, C., Tansey-Md, K. E., Walden, K., & Kirshblum, S. (2021). International Standards for Neurological Classification of Spinal Cord Injury: Revised 2019. *Topics in spinal cord injury rehabilitation*, 27(2), 1–22. <https://doi.org/10.46292/sci2702-1>