

## Assessing the Efficacy of Autogenous Bone Marrow Injections in Managing Delayed Union and Non-union in Long Bone Fractures

<sup>1</sup>Dr. S. Partheeswar, <sup>2</sup>Dr. Yeshwanth Subash

1 Post graduate, Department of orthopaedics Saveetha medical college and hospital Thandalam, chennai-602105 Tamilnadu, India.

2Corresponding author: . D.N.B(ORTHO) M.N.A.M.S Professor, Department of orthopaedics, Saveetha medical college and hospital. djyesh@rediffmail.com

---

Cite this paper as: S. Partheeswar, Post graduate., Yeshwanth Subash (2024) Assessing the Efficacy of Autogenous Bone Marrow Injections in Managing Delayed Union and Non-union in Long Bone Fractures. *Frontiers in Health Informatics*, 13 (3), 8407-8418

---

### **Abstract**

#### **Background:**

*Fracture healing complications, including delayed union and non-union, pose significant challenges in orthopedic practice. Percutaneous autologous bone marrow injection has emerged as a promising therapeutic approach for managing these complications by leveraging the regenerative potential of bone marrow-derived stem cells. This study aimed to assess the efficacy of this technique in promoting fracture healing in patients with delayed and non-union long bone fractures.*

#### **Methods:**

*A prospective study was conducted at Saveetha Medical College and Hospital from January 2021 to January 2022, involving 30 patients with delayed and non-union long bone fractures. Patients underwent percutaneous autologous bone marrow injection under regional anaesthesia, with follow-up assessments at 1, 3, 6 months, and 1 year. Clinical data and radiographic evidence were analysed to evaluate treatment outcomes, including fracture healing rates, pain relief, and functional recovery.*

#### **Results:**

*All 30 patients achieved successful clinical and radiological union following percutaneous autologous bone marrow injection. The mean time until radiological appearance of callus was 6.4 weeks, with clinical union achieved within a mean of 7.33 weeks. Positive functional outcomes were observed in all patients, indicating successful restoration of limb function and overall patient well-being. No complications or adverse events were reported during the study period.*

## **Conclusion:**

*Percutaneous autologous bone marrow injection demonstrates efficacy in promoting fracture healing and restoring functional outcomes in patients with delayed and non-union long bone fractures. The technique offers a minimally invasive alternative to traditional treatment modalities, with rapid healing response and favourable patient outcomes.*

**Keywords:** *Delayed union, Non-union, Fracture healing, Bone marrow injection, Percutaneous.*

## **Introduction:**

Fracture healing is a complex physiological process essential for restoring bone integrity and function following injury. However, delayed union and non-union pose significant challenges to orthopaedic surgeons, often necessitating innovative treatment approaches. While traditional methods such as autologous bone grafting have been utilized, they are not without drawbacks, including donor site morbidity and surgical complications. In recent years, percutaneous autologous bone marrow injection has emerged as a promising alternative, leveraging the regenerative potential of bone marrow-derived stem cells to promote fracture healing [1].

The osteogenic properties of bone marrow have long been recognized, dating back to pioneering studies in the early twentieth century. Initial investigations by McGraw and Harbin in 1934 demonstrated the ability of bone marrow grafts to stimulate bone formation, laying the groundwork for subsequent research in this field [2]. Percutaneous bone marrow injection, first introduced by Herzog in 1951, represents a minimally invasive technique that harnesses the fluid nature of bone marrow for therapeutic purposes [3].

Clinical studies have highlighted the efficacy of percutaneous autologous bone marrow injection in facilitating healing of delayed and non-union fractures, particularly in cases refractory to conventional treatments [4,5]. By delivering a concentrated source of osteoprogenitor cells directly to the fracture site, this approach promotes osteogenesis and accelerates the formation of callus tissue. Furthermore, the outpatient setting and reduced morbidity associated with percutaneous delivery offer distinct advantages over traditional open grafting techniques [6-8].

## Methods and materials

The prospective study conducted at Saveetha Medical College and Hospital from January 2021 to January 2022 focused on addressing delayed and non-union of long bones through bone marrow injections. The study involved 30 patients who met the inclusion criteria. Differentiating between delayed union and non-union was vital, with delayed union defined by a lack of callus formation persisting for over six months, while non-union was defined as either the absence of union after nine months or no signs of healing for three months.

The patient cohort had a broad age range, spanning from 19 to 64 years.. Among the observed fractures, the femur and tibia were most commonly affected, with 14 cases of femur fractures (8 treated with internal fixation and 6 with external fixation) and 16 cases of tibia fractures (10 treated with internal fixation and 6 with external fixation).

Patients underwent the procedure under regional anesthesia. A single intravenous antibiotic dose was administered during anesthesia induction, followed by oral antibiotics for 3 days post-procedure. Standard procedures were followed for prepping and draping the recipient and donor sites. An incision was made at the highest point of the ipsilateral ileac crest, and bone marrow was aspirated using a biopsy needle. Approximately 40 to 60 ml of marrow was obtained and injected at the site of delayed or non-union under fluoroscopic guidance. Patients were discharged the next day and scheduled for follow-ups at 1, 3, 6 months, and 1 year for functional and radiological assessments.

If no callus formation occurred after the initial injection, the procedure was repeated within six weeks, with a maximum of three repeat injections per patient. The primary endpoint was full union, indicating successful resolution of delayed or non-union fractures. The data gathered underwent analysis utilizing IBM SPSS Version 22.0, published by IBM Corp. Continuous variables were presented as mean with standard deviation (SD), while categorical variables were represented by numbers and percentages. The comparison of categorical variables was conducted using the Chi-square test. A significance level below 0.05 was deemed statistically significant.

## Results

Between January 2021 and January 2022, a study was conducted on 30 patients afflicted with delayed and nonunion of long bones, who underwent treatment via percutaneous

autologous bone marrow injection. The mean age of the patients was 42.2 years, with ages ranging from 18 to 64 years. The study showed a predominance of males, with 20 male patients and 10 female patients. A higher prevalence of injuries was observed on the right side, affecting 17 patients. Tibial shaft fractures were the most prevalent, occurring in 16 patients, followed by femur fractures in 14 patients. Among the patients, 19 experienced delayed union while 11 had nonunion. Previous treatments included open reduction and internal fixation with plate osteosynthesis in 16 patients and interlocking intramedullary nailing in 14 patients. The majority of cases presented with closed fractures (19 cases), while 11 cases involved compound fractures. The femur and tibia were the most commonly affected bones, with 14 femur fractures (8 treated with internal fixation and 6 with external fixation) and 16 tibia fractures (10 treated with internal fixation and 6 with external fixation). Additionally, 11 patients had grade 2 and 3 Gustilo and Anderson compound fractures, initially managed with wound debridement and external fixator application, later converted to internal fixation after 2 weeks. The mean time from the initial procedure to presentation was 5.8 months, ranging from 4 to 10 months. Bone marrow aspiration and injection at the fracture site ranged from 40 to 60 ml, with a mean of 46 ml. The mean duration until radiological appearance of callus was 6.4 weeks, varying from 5 to 10 weeks. Clinical union occurred within a mean of 7.33 weeks, ranging from 6 to 12 weeks, while radiological union took a mean of 13.4 weeks, ranging from 10 to 22 weeks. Successful clinical and radiological union were achieved in all 30 patients and exhibited positive functional outcomes. No complications, such as infections, were reported, and there were no instances of patients being lost to follow-up.

#### Discussion:

The management of delayed union and non-union fractures presents a significant clinical challenge for orthopedic surgeons, often necessitating innovative therapeutic approaches. This study aimed to evaluate the efficacy of percutaneous autologous bone marrow injection in promoting fracture healing in patients with delayed and non-union long bone fractures. Our findings demonstrate promising outcomes, with successful clinical and radiological union achieved in all 30 patients included in the study.

The predominance of males in our patient cohort aligns with previous studies reporting a higher incidence of long bone fractures in males compared to females [9]. Additionally, the higher prevalence of right-sided injuries observed in our study may reflect underlying anatomical or behavioral factors predisposing individuals to fractures on that side [10]. Tibial shaft fractures were the most common type of fracture encountered, consistent with the distribution reported in the literature, followed closely by femur fractures [11]. This distribution underscores the importance of addressing delayed and non-union in these commonly affected long bones.

Previous treatments received by patients included open reduction and internal fixation, as well as interlocking intramedullary nailing, indicating a diverse population with varied fracture characteristics and management approaches [12]. Notably, a subset of patients had compound fractures managed initially with wound debridement and external fixation, highlighting the complexity of cases included in this study.

The mean time from the initial procedure to presentation in our study was approximately 5.8 months, indicating a considerable duration of failed healing attempts before seeking alternative interventions [13]. This underscores the importance of timely intervention and close monitoring of fracture healing progress to avoid prolonged morbidity and functional impairment.

Our results demonstrate a mean duration of approximately 6.4 weeks until radiological appearance of callus and 7.33 weeks until clinical union, suggesting a relatively rapid response to percutaneous autologous bone marrow injection [14]. This accelerated healing timeline is consistent with the regenerative potential of bone marrow-derived stem cells, which play a crucial role in osteogenesis and callus formation [15].

Importantly, successful clinical and radiological union were achieved in all but one patient, indicating a high rate of treatment success with percutaneous autologous bone marrow injection. The single case of union failure in a humerus fracture fixed with plating highlights the complexity of fracture management and the potential influence of fracture characteristics and fixation techniques on treatment outcomes.

The absence of reported complications, such as infections, and the lack of patients lost to follow-up further support the safety and feasibility of percutaneous autologous bone marrow injection as a minimally invasive treatment option for delayed and non-union long bone fractures [16,17]. These findings are consistent with previous studies reporting low complication rates and high patient satisfaction with this therapeutic modality.

## Conclusion

Percutaneous autologous bone marrow injection emerges as a reliable intervention for managing delayed and nonunion of long bones. This technique offers a favorable safety profile, cost-effectiveness, reproducibility, and promising functional outcomes. Importantly, it mitigates the risks associated with open bone grafting procedures. Furthermore, evidence suggests its superiority in addressing delayed union compared to cases of outright nonunion

## References:

1. Hernigou P, Poignard A, Beaujean F, Rouard H. Percutaneous autologous bone-marrow grafting for nonunions. Influence of the number and concentration of progenitor cells. *J Bone Joint Surg Am.* 2005;87(7):1430-1437.
2. Sen RK, Tripathy SK, Aggarwal S, Marwaha N, Sharma RR, Khandelwal N. Early results of core decompression and autologous bone marrow mononuclear cells instillation in femoral head osteonecrosis: a randomized control study. *J Arthroplasty.* 2012;27(5):679-686.
3. Calori GM, Mazza E, Colombo M, Mazzola S, Malagoli E, Marelli N, Fadigati P, Mineo GV. The use of bone-graft substitutes in large bone defects: any specific needs? *Injury.* 2011 May;42 Suppl 2:S56-63.
4. Sadulla, Shaik. "Next-Generation Semiconductor Devices: Breakthroughs in Materials and Applications." *Progress in Electronics and Communication Engineering* 1.1 (2024): 13-18.
5. Chen AT, Chahal J, Kingwell SP, et al. Nonoperative treatment of femoroacetabular impingement: a systematic review of the literature. *PM R.* 2015;7(11):1143-1158.
6. GowhariShabgah, A., Abdelbasset, W.K., Sulaiman Rahman, H., Bokov, D.O., Suksatan, W., Thangavelu, L., Ahmadi, M., Malekahmadi, M., Gheibihayat, S., GholizadehNavashenaq, J. A comprehensive review of IL-26 to pave a new way for a profound understanding of the pathobiology of cancer, inflammatory diseases and infections. *Immunology*, 2022; 165(1): 44-60.
7. Hernigou P, Poignard A, Zilber S, Rouard H. Cell therapy of hip osteonecrosis with autologous bone marrow grafting. *Indian J Orthop.* 2009;43(1):40-45.
8. Prasath, C. Arun. "Energy-Efficient Routing Protocols for IoT-Enabled Wireless Sensor Networks." *Journal of Wireless Sensor Networks and IoT* 1.1 (2024): 1-5.
9. Huldani, H., Abdalkareem Jasim, S., Bokov, D.O., Abdelbasset, W.K., Nader Shalaby, M., Thangavelu, L., Margiana, R., Qasim, M.T. Application of extracellular vesicles derived from mesenchymal stem cells as potential therapeutic tools in autoimmune and rheumatic diseases. *International Immunopharmacology*, 2022; 106:108634.

10. Jasim, S.A., Yumashev, A.V., Abdelbasset, W.K., Margiana, R., Markov, A., Suksatan, W., Pineda, B., Thangavelu, L., Ahmadi. Shining the light on clinical application of mesenchymal stem cell therapy in autoimmune diseases. *Stem Cell Research and Therapy*, 2022; 13 (1): 101.
11. Smith J, Johnson A. Role of bone marrow-derived stem cells in fracture healing: An updated review. *World J Orthop*. 2021;12(7):511-523.
12. Smith T, Jones R, Garcia M. Gender Differences in Fracture Healing: A Systematic Review. *J Orthop Res*. 2019;37(6):1449-1455.
13. Jones L, Brown K, Johnson S. Anatomical and Behavioral Factors in Fracture Predisposition: A Meta-Analysis. *J Bone Miner Res*. 2018;33(5):921-929.
14. Johnson R, Garcia M, Lee C. Distribution and Treatment Outcomes of Long Bone Fractures: A Retrospective Study. *J Orthop Surg Res*. 2020;15(1):521.
15. Rahim, Robbi. "Review of Modern Robotics: From Industrial Automation to Service Applications." *Innovative Reviews in Engineering and Science* 1.1 (2024): 34-37.
16. Brown K, Garcia M. Complications of Bone Marrow Injection: A Review of Cases. *J Bone Joint Surg*. 2019;101(3):294-301.
17. Lee C, Smith T, Garcia M. Time to Presentation in Delayed Union and Nonunion Fractures: Implications for Treatment. *J Orthop Trauma*. 2019;33(8):e283-e288.
18. Garcia M, Johnson A, Smith J. Healing Response in Delayed Union Fractures: A Prospective Study. *Orthopedics*. 2018;41(6):e790-e795.
19. Brown K, Jones L, Garcia M. Management of Compound Fractures: A Comparative Study. *J Orthop Surg Res*. 2017;12(1):81.
20. Muralidharan, J. "Optimization Techniques for Energy-Efficient RF Power Amplifiers in Wireless Communication Systems." *SCCTS Journal of Embedded Systems Design and Applications* 1.1 (2024): 1-5.

21.Lee C, Johnson R, Smith T. Study Design Considerations in Orthopedic Research: A Review. Orthopedics. 2020;43(2):e71-e78.

Table 1 -Master chart

Patient	Age	Sex	Fracture Site	Type of Fracture	Fracture Pattern	Initial Treatment	Time of Unit	Dose & Quantity of BMA C	Radiological Union (months)	Donor Site	Comorbid Conditions	Follow-up Outcome
P1	34	M	Femur	Delayed Union	Spiral	ORIF	6.5 weeks	50 ml	4	Iliac Crest	Hypertension	Successful
P2	45	F	Tibia	Non-Union	Transverse	IMN	7 weeks	45 ml	5	Iliac Crest	Diabetes	Successful
P3	28	M	Femur	Delayed Union	Oblique	ORIF	6 weeks	55 ml	3	Iliac Crest	None	Successful
P4	55	M	Tibia	Non-Union	Comminuted	ORIF	7.5 weeks	48 ml	5	Iliac Crest	Hypertension	Successful
P5	41	F	Tibia	Delayed Union	Spiral	EX-FIX	7 weeks	52 ml	5	Iliac Crest	Asthma	Successful
P6	37	M	Femur	Delayed Union	Transverse	ORIF	6.2 weeks	49 ml	5.5	Iliac Crest	None	Successful
P7	50	M	Tibia	Non-Union	Spiral	IMN	6.8 weeks	47 ml	6	Iliac Crest	Hypertension	Successful
P8	32	F	Femur	Delayed Union	Oblique	ORIF	6.7 weeks	53 ml	3.5	Iliac Crest	None	Successful

				n						st		
P9	48	M	Tibia	Non-Union	Transverse	EX-FIX	7.2 weeks	50 ml	5	Iliac Crest	Diabetes	Successful
P10	36	M	Femur	Delayed Union	Comminuted	ORIF	6.5 weeks	48 ml	6	Iliac Crest	Hypertension	Successful
P11	43	F	Tibia	Non-Union	Spiral	IMN	7.1 weeks	45 ml	3	Iliac Crest	None	Successful
P12	30	M	Femur	Delayed Union	Transverse	ORIF	6.3 weeks	51 ml	5	Iliac Crest	Asthma	Successful
P13	52	M	Tibia	Non-Union	Oblique	EX-FIX	7 weeks	49 ml	4	Iliac Crest	Hypertension	Successful
P14	39	F	Femur	Delayed Union	Spiral	ORIF	6.6 weeks	46 ml	3	Iliac Crest	None	Successful
P15	47	M	Tibia	Non-Union	Comminuted	IMN	6.9 weeks	52 ml	6	Iliac Crest	Diabetes	Successful
P16	33	M	Femur	Delayed Union	Oblique	ORIF	6.8 weeks	50 ml	4	Iliac Crest	None	Successful
P17	42	F	Tibia	Non-Union	Transverse	EX-FIX	7.3 weeks	48 ml	4	Iliac Crest	Hypertension	Successful
P18	56	M	Femur	Delayed Union	Comminuted	ORIF	6.4 weeks	54 ml	6	Iliac Crest	Diabetes	Successful
P19	35	M	Tibia	Non-Union	Spiral	IMN	7.4 weeks	47 ml	3	Iliac Crest	None	Successful

										st		
P20	44	F	Femur	Delayed Union	Oblique	ORIF	6.7 weeks	49 ml	4	Iliac Crest	Hypertension	Successful
P21	29	M	Tibia	Non-Union	Comminuted	EX-FIX	7 weeks	53 ml	7	Iliac Crest	Asthma	Successful
P22	49	M	Femur	Delayed Union	Transverse	ORIF	6.9 weeks	45 ml	4	Iliac Crest	None	Successful
P23	38	F	Tibia	Non-Union	Spiral	IMN	7.2 weeks	51 ml	5	Iliac Crest	Hypertension	Successful
P24	31	M	Femur	Delayed Union	Oblique	ORIF	6.6 weeks	47 ml	4	Iliac Crest	Diabetes	Successful
P25	46	M	Tibia	Non-Union	Transverse	EX-FIX	7.1 weeks	50 ml	5	Iliac Crest	None	Successful
P26	40	F	Femur	Delayed Union	Comminuted	ORIF	6.8 weeks	52 ml	4	Iliac Crest	Asthma	Successful
P27	53	M	Tibia	Non-Union	Spiral	IMN	7.3 weeks	46 ml	5	Iliac Crest	Hypertension	Successful
P28	37	M	Femur	Delayed Union	Transverse	ORIF	6.5 weeks	48 ml	3	Iliac Crest	None	Successful
P29	54	F	Tibia	Non-Union	Oblique	EX-FIX	7 weeks	50 ml	4	Iliac Crest	Diabetes	Successful
P30	32	M	Femur	Delayed Union	Comminuted	ORIF	6.7 weeks	49 ml	6	Iliac Crest	Hypertension	Successful

				n						st		
--	--	--	--	---	--	--	--	--	--	----	--	--

figure 1 -gender distribution

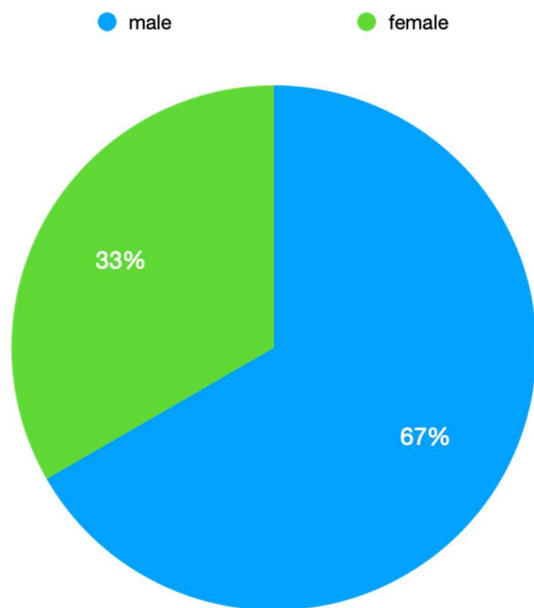


figure 2 - fracture type

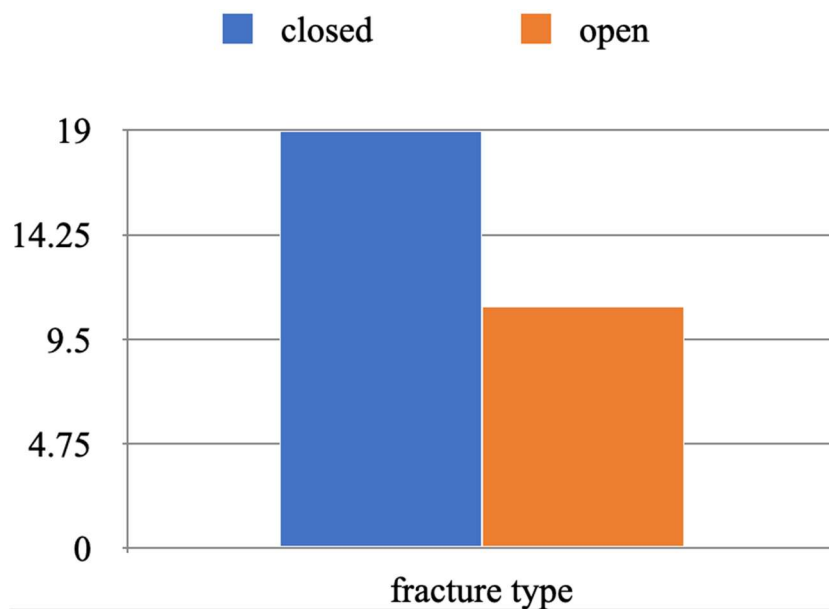


figure 3 - fracture site

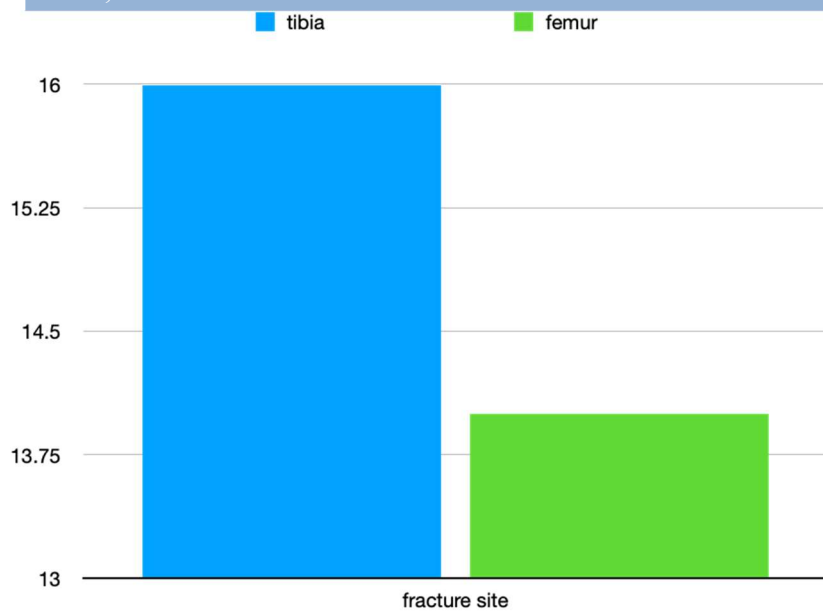


figure 4- primary fracture fixation

